

Original Article

One-stage extreme lateral interbody fusion and percutaneous pedicle screw fixation in lumbar spine tuberculosis

Q-Y. Wang^{1, #}, M-G. Huang^{2, #}, D-Q. Ou^{2, #}, Y-C. Xu¹, J-W. Dong¹, H-D. Yin², W. Chen², L-M. Rong¹¹Department of Spine Surgery, The third Affiliated Hospital of Sun Yat-sen University, No. 600, Tianhe Road, Tianhe District, Guangzhou 510630, China;²Department of Orthopaedics, The first People's Hospital of Shunde, No. 1, Penglai Road, Shunde District, Foshan 528300, China

equal contribution

Abstract

Objectives: We explored the efficacy of minimal invasive surgery including one-stage debridement and intervertebral fusion through extreme lateral channel (XLIF) combined with lateral or percutaneous posterior pedicle screw fixation for the treatment of lumbar spine tuberculosis. **Methods:** Twenty two patients with lumbar tuberculosis who underwent surgery with XLIF technique and internal fixation were included in the study. Their data about operative time, intraoperative blood loss, bone fusion, kyphosis correction, and clinical recovery were retrospectively collected and analyzed. **Results:** The mean intraoperative blood loss was 249.8 ± 27.8 ml and the operative time 347.5 ± 20.7 min. At the final follow-up, 11 to 15 months postoperatively, ESR and CRP were normal and pain (VAS) and Oswestry disability index (ODI) were significantly reduced (23.0 ± 3.1 vs 0.6 ± 0.7 and 57.2 ± 1.6 vs 6.4 ± 1.2 respectively) compared to preoperative values. Progression of the kyphotic deformity was effectively prevented (mean Cobb angle $23.9^\circ \pm 1.9^\circ$ vs $24.5^\circ \pm 1.4^\circ$, $P > 0.05$). There was one failure of the fixation associated to poor therapy adherence. All the patients showed neurological recovery. **Conclusion:** Debridement and interbody fusion by extreme lateral channel combined with lateral or percutaneous posterior pedicle screw fixation effectively retained the spine stability and provided clinical and neurologic recovery in selected patients with lumbar spine tuberculosis.

Keywords: Spinal Tuberculosis, Minimal Invasive, XLIF

Introduction

Current therapeutic options for spinal tuberculosis are antituberculous therapy and conservative management with bracing or surgery¹. Many studies have confirmed the effectiveness of surgical treatment of spinal tuberculosis through anterior, anterolateral, posterior debridement and intervertebral fusion or combinations with internal fixation to improve the neurological deficit and correct the kyphotic deformity^{2,3}. However, these surgical meth-

ods are related to excessive blood loss and long operative and hospitalization time, thus are not suitable for some patients.

The XLIF is a novel surgical technique that is mainly used for spinal degenerative diseases⁴⁻⁷, or adult degenerative scoliosis^{8,9}. Pimenta et al.¹⁰ verified the feasibility of total lumbar disc replacement through the extreme lateral approach.

Considering the particular biomechanics and anatomy of lumbar spinal tuberculosis compared to other segments, we applied XLIF, a minimally invasive technique in patients with tuberculosis located in the lumbar spine. In our study, 22 patients with lumbar spine tuberculosis and an indication for surgical therapy, were managed by one-stage debridement and fusion with a cage or bone graft through the extreme lateral interbody (XLIF) channel combined with posterior (or lateral) pedicle screw fixation and their preoperative and final data at follow-up were assessed in order to evaluate the effectiveness of the method.

The authors have no conflict of interest.

Corresponding author: Li-Min Rong, Department of Spine Surgery, The third Affiliated Hospital of Sun Yat-sen University, No. 600, Tianhe Road, Tianhe District, Guangzhou 510630, China
E-mail: li_minrong1@163.com

Edited by: G.P. Lyritis
Accepted 29 September 2016

Table 1. The clinical general data of patients with lumbar tuberculosis.

General data	Cases(n)/Description
Number of males/females	12/10
Lesion location(n=22)	
L2/3	3
L3/4	11
L4/5	8
Duration of operation (min)	347.5 ± 20.7
Blood loss (ml)	249.8 ± 27.8
Time in hospital (d)	25.8 ± 1.9

Table 2. Clinical assessment and Frankel grade of patients before surgery and final follow up.

Content	Preoperation	Final follow-up	P	Frankel grade	Preoperative grade	Postoperative grade	Final follow-up
Low back ache visual analog scale(VAS)	6.4 ± 1.2	0.6 ± 0.7	P<0.05	C	2	0	0
Oswestry Disability Index(ODI)	57.2 ± 6.1	23.0 ± 3.1	P<0.05	D	14	1	0
Erythrocyte sedimentation rate, mm/h	26.4 ± 4.0	7.9 ± 1.2	P<0.05	E	6	21	22
C-reactive protein, mg/L	23.8 ± 1.9	4.0 ± 1.4	P<0.05				

Table 3. Imaging analysis in global lumbar lordosis. * L1-L5: Measurement method: superior border of L1 vertebra to inferior border of L5 vertebra. ** No significant difference was found between the preoperative and final follow-up (p>0.05).

Content	Preoperation	Final follow-up
cobb angle(L1-L5*)	23.9 ± 1.9	24.5 ± 1.4 **

Subjects and methods

Twelve men and ten women 28 to 79 years old, with lumbar spine tuberculosis who underwent XLIF and debridement combined with percutaneous or lateral pedicle screw fixation between October 2012 and March 2014 and had completed the one-year follow-up, were included in the study (Table 1). All patients had clinical evident disease with pain, fatigue, night sweats, low fever, and weight loss for 0.5 to 12 months (mean 0.5-12 months). Among them sixteen had neurological deficits. The FRANKEL grade classification of spinal nerve injury was D in

14 patients, C in 2 patients, and the rest were normal (E). Diagnosis was confirmed by x-rays, magnetic resonance imaging (MRI) or computed tomography (CT) imaging, laboratory erythrocyte sedimentation rate (ESR) and C-reactive protein (CRP). The final pathological examination of lesion was the gold standard to diagnosis. After the preliminary diagnosis the patients received the conventional standard antituberculosis treatment including rifampicin (450 mg per day, orally), isoniazid (300 mg per day, orally), pyrazinamide (750 mg per day, orally), and Streptomycin (75 mg per day, intramuscular injection). The preoperative drug treatment lasted for at least two weeks. The surgical indications included the unstable spine caused by

vertebral destruction and deformity, nerve function injury, or abscess around the lesion. The patients had spondylitis located to one intervertebral segment (Table 1). All the patients signed an informed consent before the operation. The operations were conducted by experienced surgeons whose professional titles were above associate professor.

Surgical technique

Four critical steps were included in this surgical technique.

1) Surgical position

After a successful intratracheal intubation of anesthesia, the patients were positioned in lateral decubitus position. To relax the psoas and to increase the distance between the thorax and iliac crest, we flexed the hip joint in the left lower limb and adjusted the head and tailstock of the operating bed. Adhesive tapes were used to fix the trunk and lower limbs. Before routine disinfection, cross K-wires were used to locate the anteroposterior and lateral view of the major segment or intervertebral space under fluoroscopy.

2) Establishment of surgical channel through the lateral approach

First, the skin incision (about 3-4 cm in length) was performed to the vertical K-wires and aimed to the middle of the upper and lower end plate before establishing the lateral approach and dilator. A primary dilator was used to separate the psoas, and a guiding pin was placed to the lateral of the intervertebral disc through primary dilator under X-ray fluoroscopy. Expansion tubes of different diameters were used and the final dilator was hooked up to the free arm and fixed beside the operating bed. Afterward, a light source was installed to the dilator.

3) Debridement and fusion in the intervertebral space

The annulus of the object's intervertebral disc was cut with a sharp blade through the surgical channel under direct vision. Necrotic tissues, including nucleus pulposus, adjacent end plate and vertebra, and abscess, were removed with different types of curettes and rongeurs. After the clearance of lesions, the intervertebral fusion material (e.g., titanium mesh and or autologous iliac crest) with streptomycin powder was positioned between the two vertebral bodies according to the size of molding. Finally, a routine drainage tube was placed after surgery.

4) Minimally invasive posterior pedicle screws fixation

The patient was changed to the prone position, and the entry point of percutaneous pedicle screws under the AP X-ray was secured. Four 6.5 mm × 45 mm titanium screws (VIPER II, Depuy Spine) were used to place the four K-wires at the objective vertebra. Finally, pedicle-rods were passed through the relevant trajectory of pedicle screws under the VIPER II system.

Postoperative treatment

Routine prophylactic antibiotic therapy was given for 3-5 days, while the conventional antituberculosis drugs were continued for 12-18 months. The drainage was removed when the volume was less than 50 ml. The patients stayed in bed for 1 week postoperatively and gradually started walking with waistlines recommended for at least 6 months. The conventional clinical evaluation and imaging follow-ups were performed in the 3rd, 6th, and 12th postoperative months. ESR and CRP were measured at the final follow-up. Successful bone fusion was evaluated according to criteria established by Moon et al; no loss of correction, no graft resorption or graft bed resorption, and if there was visible graft remodeling, such as trabeculation between the graft beds and graft and the graft hypertrophy¹¹. The clinical assessment of patients included the assessments of Visual analogue scale of pain (VAS) and the Oswestry disability index (ODI) and the FRANKEL grade classification to evaluate the neuro functional recovery. The data were reviewed and statistical analysis was performed with paired t-test. P<0.05 was taken as the threshold value to judge statistical significance.

Results

The mean follow-up time was 12.4±1.1 months (11 to 15 months). Data about the level of the spondylodiscitis, the operative time, intraoperative blood loss and hospitalization time are shown in Table 1. Table 2 summarizes the laboratory and clinical indices of the disease and their postoperative recovery at the final follow-up. All the patients who were neurologically comprised preoperatively showed neurological improvement. The majority of them (14 patients) moved from Frankel D preoperatively to Frankel E, at the final follow up.

Postoperatively, bone interbody fusion obtained by different types of graft/implants was generally good (Figure 1). The internal fixation loosened in one case after the operation which was attributed to drug treatment disobedience and earlier frequent activities. The postoperative spinal deformity correction effect achieved good results through the imaging analysis (p>0.05) (Table 3). No case except the one mentioned before had lost the correction at the last follow-up. This patient was treated by evacuation of the psoas abscess and improvement of the adherence to drug therapy.

Discussion

Many clinical studies have proven the effectiveness and security of anterior approach by XLIF in degenerative spinal diseases⁴⁻¹¹. However the method has rarely been reported for treating spinal infections such as spondylodiscitis and tuberculosis spondylitis. In the present study, we proposed a novel treatment strategy for lumbar tuberculosis, in which the lesions could be removed via the extreme lateral mini-invasive approach.

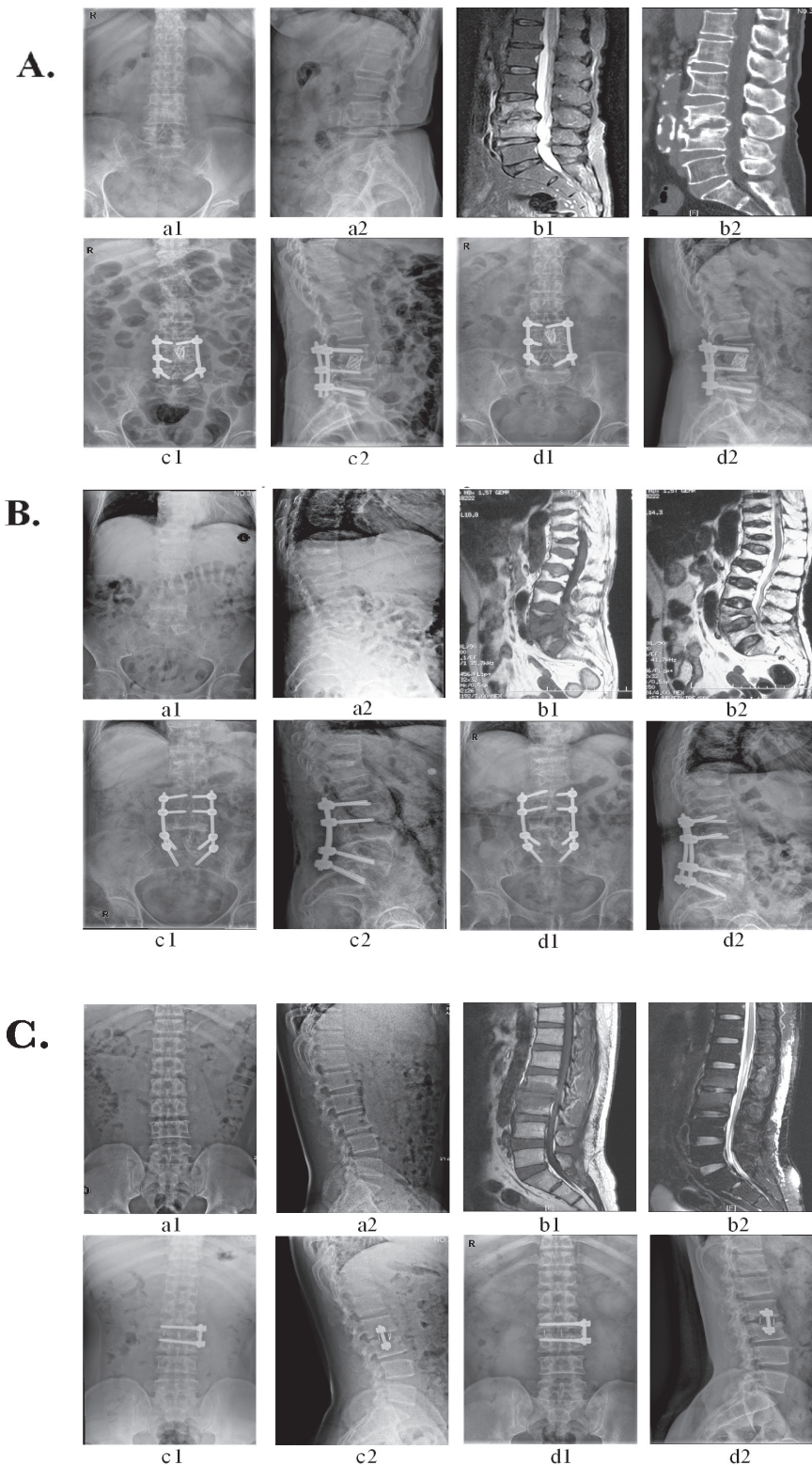


Figure 1. **A)** A 60 year old woman with spinal tuberculosis in L3-L4 **B)** A 79 year old female patient presented with low back pain due to destructive spinal tuberculosis at L4-L5 with a mild paravertebral abscess. **C)** A 36 year old male diagnosed with L2-L3 spinal tuberculosis. A titanium (A) (OR: Autologous bone grafting (B), Cage (C)) were instrumented anteriorly, and correction of kyphosis deformity was obtained after posterior percutaneous pedicle screws fixation (A, B) (OR: Lateral pedicle screws fixation (C)). Preoperative a1, a2 X-ray radiographs (Anterior and Lateral position) and b1, b2 sagittal MRI or CT, and c1,c2 postoperative X-ray radiographs and d1, d2 one year follow up X-ray radiographs.

We should be aware of the neurological complications related to this approach. Nerve injury is a complication that should always be considered a priority during surgery. With more and more applications of electromyography, postoperative neurological deficits could be effectively prevented by this special recording technique¹². In spite of this, the failure of intraoperative monitoring to detect nerve injury could still not be completely avoided. Houten et al.¹³ advised that surgeons should not simply rely on electrophysiological monitoring. Moreover, anatomical studies and radiographic assessments¹⁴⁻¹⁷ have been used for the early prevention of related complications. Tormenti et al. reported a high complication rate with XLIF during the perioperative period¹⁸, but the small sample size represents one of the limitations of this study. To avoid limitations that result from a small sample size, a series of large studies were conducted. They revealed that the incidence of complications after XLIF surgery is not high¹⁹. In conclusion, a comprehensive preoperative assessment is important before treating lumbar infections to prevent many of the complications associated with the extreme lateral approach. The follow-up study showed that no case of nerve function damage was found, which may be related to G arm machine positioning before operation; more attention was given in L4/5 segmental localization²⁰⁻²². We did not observe spinal cord injury or other obvious complications in the patient.

Another considerable issue is the rate of bone fusion after surgery. Many studies demonstrated that the bone fusion rate after XLIF is high^{23,24}. In our study a high bone fusion rate was found, and bone healing was completed at the one-year follow-up (Figure 1). Although a loss of the Cobb angle existed at the final follow-up, the imaging examination revealed that the stability of the spine was preserved. Moreover, quality of life significantly improved, as was evident by the postoperative evaluation of ODI and VAS.

Nevertheless, the indication of this new technique for lumbar tuberculosis should be acknowledged. The following preoperative prerequisites should be noted: (1) The preoperative antituberculosis treatment reaction was well; (2) The preoperative imaging evaluation showed that the focus could be completely removed through a minimally invasive channel; Finally the third prerequisite is the stable internal fixation as an important basis for spinal reconstruction. Thus the preoperative regular antituberculosis treatment was very important. After the general conditions were improved and the erythrocyte sedimentation rate was significantly decreased, the surgery was important to control the development of the disease. Moreover, the debridement range through the XL channel generally involves only the segments near the vertebral body. Therefore, the spinal tuberculous foci needed to be selected before the operation. Larger foci may not be cleared up through the channel. Destructive bone and intervertebral disc should be completely resected, and a strong fixation is necessary to obtain reduction and spinal stability to successfully implant the autologous bone and internal fixation materials. Posterior (or lateral) pedicle screw fixation was important especially for the patients with osteoporosis or with obviously unstable spine. Previous studies have proved

the necessity of posterior internal fixation on unstable spinal tuberculosis²⁵. Furthermore, screw-setting through lateral minimally invasive channel was suitable for young patients with tuberculosis (Figure 1 C). Therefore, surgeons should carefully consider the clinical indications to maximize the outcomes for the patients before using this technique for lesions where infections are present.

Improving the quality of life is a goal that we all aspire to. One of the greatest advantages of mini-invasive surgery is a more favorable postoperative recovery without extensive soft tissue dissection. Early recovery is important for spinal infectious diseases in the elderly. A study suggested that the operative time, the estimated blood loss, and the short length of hospitalization for mini-invasive lateral approach (XLIF) are significantly less than with traditional open surgery²⁶. Furthermore, Karikari et al. confirmed that elderly people also had fewer major complications after undergoing minimally invasive surgery (including XLIF and transforaminal lumbar interbody fusion)²⁷.

Although there were limited cases in this study, we believe that mini-invasive surgery through the lateral approach is a promising new treatment for lumbar tuberculosis and other infectious diseases, and its benefits should be validated in the future with large multicenter prospective studies.

References

1. Jain AK. Tuberculosis of the spine: a fresh look at an old disease. *J Bone Joint Surg Br* 2010;92:905-913.
2. Mak KC and Cheung KM. Surgical treatment of acute TB spondylitis: indications and outcomes. *Eur Spine J* 2013;22(Suppl 4):603-611.
3. Panchmatia JR, Lenke LG, Molloy S et al. Review article: Surgical approaches for correction of post-tubercular kyphosis. *J Orthop Surg* 2015;23(3):391-4.
4. Ozgur BM, Aryan HE, Pimenta L and Taylor WR. Extreme Lateral Interbody Fusion(XLIF): a novel surgical technique for anterior lumbar interbody fusion. *Spine J* 2006;6:435-443.
5. Rodgers WB, Lehmen JA, Gerber EJ and Rodgers JA. Grade 2 spondylolisthesis at L4-5 treated by XLIF: safety and midterm results in the "worst case scenario". *Scientific World Journal* 2012;2012:356712.
6. Hrabálek L, Wanek T and Adamus M. XLIF-a new technique of the lumbar vertebra disc replacement: initial experience. *Rozhl Chir* 2010;89:784-788.
7. Youssef JA, McAfee PC, Patty CA, Raley E, DeBauche S, Shucosky E and Chotikul L. Minimally invasive surgery: lateral approach interbody fusion: results and review. *Spine (Phila Pa 1976)* 2010;35(26 Suppl):S302-311.
8. Caputo AM, Michael KW, Chapman TM Jr, Massey GM, Howes CR, Isaacs RE and Brown CR. Clinical outcomes of extreme lateral interbody fusion in the treatment of adult degenerative scoliosis. *Scientific World Journal* 2012;680643.
9. Isaacs RE, Hyde J, Goodrich JA, Rodgers WB and Phillips FM. A prospective, nonrandomized, multicenter

- evaluation of extreme lateral interbody fusion for the treatment of adult degenerative scoliosis: perioperative outcomes and complications. *Spine (Phila Pa 1976)* 2010;35(26 Suppl):S322-330.
10. Pimenta L, Oliveira L, Schaffa T, Coutinho E, Marchi L. Lumbar total disc replacement from an extreme lateral approach: clinical experience with a minimum of 2 years' follow-up. *J Neurosurg Spine* 2011;14:38-45.
 11. Moon MS, Woo YK, Lee KS, et al. Posterior instrumentation and anterior interbody fusion for tuberculous kyphosis of dorsal and lumbar spines. *Spine (Phila Pa 1976)* 1995;20:1910-1916.
 12. Jahangiri FR, Sherman JH, Holmberg A, Louis R, Elias J, Vega-Bermudez F. Protecting the genitofemoral nerve during direct/extreme lateral interbody fusion (DLIF/XLIF) procedures. *Am J Electroneurodiagnostic Technol* 2010;50:321-335.
 13. Houten JK, Alexandre LC, Nasser R, Wollowick AL. Nerve injury during the transpoas approach for lumbar fusion. *J Neurosurg Spine* 2011;15:280-284.
 14. Moro T, Kikuchi S, Konno S, Yaginuma H. An anatomic study of the lumbar plexus with respect to retroperitoneal endoscopic surgery. *Spine* 2003;8:423-428.
 15. Oliveira L, Marchi L, Coutinho E, Pimenta L. A radiographic assessment of the ability of the extreme lateral interbody fusion procedure to indirectly decompress the neural elements. *Spine (Phila Pa 1976)* 2010;35(26 Suppl):S331-337.
 16. Marulanda GA, Nayak A, Murtagh R, Santoni BG, Billys JB, Castellvi AE. A Cadaveric Radiographic Analysis on the Effect of Extreme Lateral Interbody Fusion Cage Placement with Supplementary Internal Fixation on Indirect Spine Decompression. *J Spinal Disord Tech* 2014; 27:263-270.
 17. Hu WK, He SS, Zhang SC, Liu YB, Li M, Hou TS, Ma XL, Wang J. An MRI study of psoas major and abdominal large vessels with respect to the X/DLIF approach. *Eur Spine J* 2011;20:557-562.
 18. Tormenti MJ, Maserati MB, Bonfield CM, Okonkwo DO, Kanter AS. Complications and radiographic correction in adult scoliosis following combined transpoas extreme lateral interbody fusion and posterior pedicle screw instrumentation. *Neurosurg Focus* 2010;28:E7.
 19. Rodgers WB, Gerber EJ, Patterson J. Intraoperative and early postoperative complications in extreme lateral interbody fusion: an analysis of 600 cases. *Spine (Phila Pa 1976)* 2011;1(36):26-32.
 20. Hrabálek L, Adamus M, Wanek T. Identification of the lumbosacral nerve plexus during the extreme lateral interbody fusion procedure. *Acta Chir Orthop Traumatol Cech* 2011;78:556-561.
 21. Jahangiri FR, Sherman JH, Holmberg A, Louis R, Elias J, Vega-Bermudez F. Protecting the genitofemoral nerve during direct/extreme lateral interbody fusion (DLIF/XLIF) procedures. *Am J Electroneurodiagnostic Technol* 2010;50:321-335.
 22. Papanastassiou ID, Eleraky M, Vrionis FD. Contralateral femoral nerve compression: An unrecognized complication after extreme lateral interbody fusion (XLIF). *J Clin Neurosci* 2011;18:149-151.
 23. Tohmeh AG, Watson B, Tohmeh M, Zielinski XJ. Allograft cellular bone matrix in extreme lateral interbody fusion: preliminary radiographic and clinical outcomes. *Scientific World Journal* 2012;2012:263637.
 24. Malham GM, Ellis NJ, Parker RM, Seex KA. Clinical outcome and fusion rates after the first 30 extreme lateral interbody fusions. *Scientific World Journal* 2012;2012: 246989.
 25. Jain AK, Dhammi IK, Prashad B, Sinha S, Mishra P. Simultaneous anterior decompression and posterior instrumentation of the tuberculous spine using an anterolateral extrapleural approach. *J Bone Joint Surg Br* 2008;90:1477-1481.
 26. Smith WD, Christian G, Serrano S, Malone KT. A comparison of perioperative charges and outcome between open and mini-open approaches for anterior lumbar discectomy and fusion. *J Clin Neurosci* 2012;19:673-680.
 27. Karikari IO, Grossi PM, Nimjee SM, Hardin C, Hodges TR, Hughes BD, Brown CR, Isaacs RE. Minimally invasive lumbar interbody fusion in patients older than 70 years of age: analysis of peri- and postoperative complications. *Neurosurgery* 2011;68:897-902.