

Clinical Quiz

Buschke-Ollendorff syndrome accidentally diagnosed after a left ankle sprain

P. Lygdas¹, E.G. Ballas², I. P. Stathopoulos³, T. Theologis¹, K. Pistevos¹, D. Pasparakis¹

¹Orthopaedic Department, Athens Pediatric Hospital 'P.& A. Kiriakou' Athens, Greece; ²First Orthopaedic Department, University of Athens, Attikon University Hospital, Athens, Greece; ³Third Orthopaedic Department, University of Athens, KAT Hospital, Athens, Greece

Keywords: Osteopoikilosis, Skin Lesions, Buschke-Ollendorff Syndrome

Case

A 9-year-old girl was referred to our clinic for evaluation of a spherical sclerotic bone lesion in the distal metaphysis of the left tibia (Figure 1A). The lesion was accidentally found after a routine radiograph for a minor left ankle injury she sustained a week earlier.

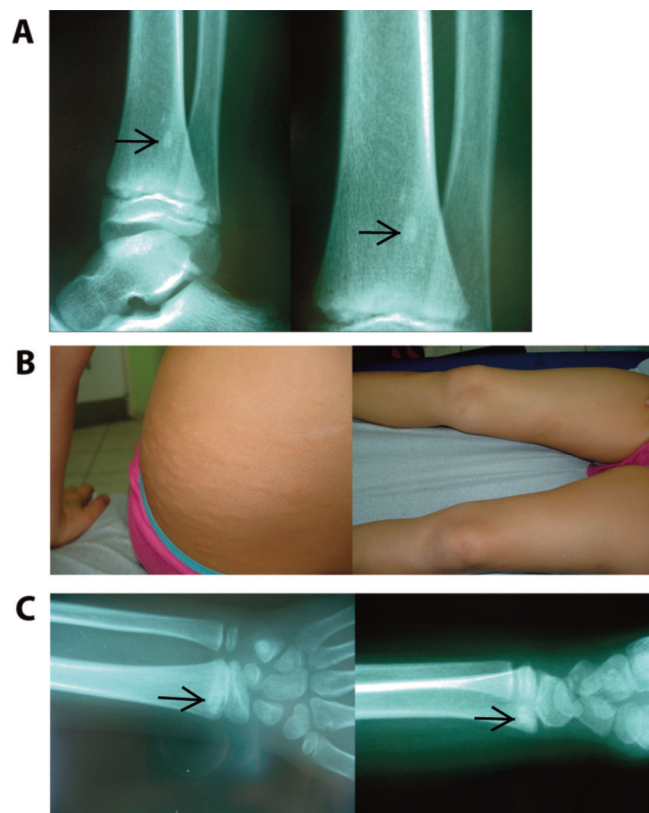
Physical examination revealed multiple, asymptomatic, symmetrically located skin lesions on either side of the lower back and proximal thighs. These lesions had smooth surface with disseminated texture and did not coalesce to form plaques (Figure 1B). No pain or pruritus was present. These findings have been present for the past 4 years but no diagnosis was made or any treatment initiated, since all the clinical and laboratory tests performed in the past were normal. Her past medical history was largely unremarkable as well as her family history for any type of skin disorders.

Routine laboratory tests (blood cell counts, ESR, CRP, liver and renal function levels as well as calcium and phosphate levels) were within normal limits. A radiographic skeletal survey was ordered. Radiographs demonstrated multiple well defined solitary sclerotic lesions on the distal metaphysis of the left tibia and both radii, consistent with osteopoikilosis (Figure 1C). Further X-rays of hands, feet, lumbar spine and pelvis showed no abnormalities. Bone lesions exhibited no increased radioisotope uptake during the three phases of the bone scanning with Tc^{99m} (Figure 2A). MRI of the left tibia revealed a solitary, well-circumscribed, lesion off 4 mm in diameter with no uptake of the paramagnetic substance. Periosteal reaction was

not recognized in the examined area and the surrounding soft tissues were intact (Figure 2B).

A punch biopsy of a skin lesion from her left thigh revealed thick collagen fibers through the dermis consistent with dermatofibrosis lenticularis disseminata. The characteristic bone

Figure 1. **A.** Sclerotic bone lesion in the distal metaphysis of the left tibia. **B.** Cutaneous lesions located on either side of the lumbar spine and proximal thighs. **C.** Ovoid sclerotic bone lesions on the distal metaphysis of both radii.



The authors have no conflict of interest.

Corresponding author: Efsthathios G. Ballas, MD, MSc, First Orthopaedic Department, University of Athens, 16 Perikleous Street, Athens, Melissia, Greece
E-mail: efsthathios.ballas@gmail.com

Edited by: P. Makras

Accepted 14 December 2013

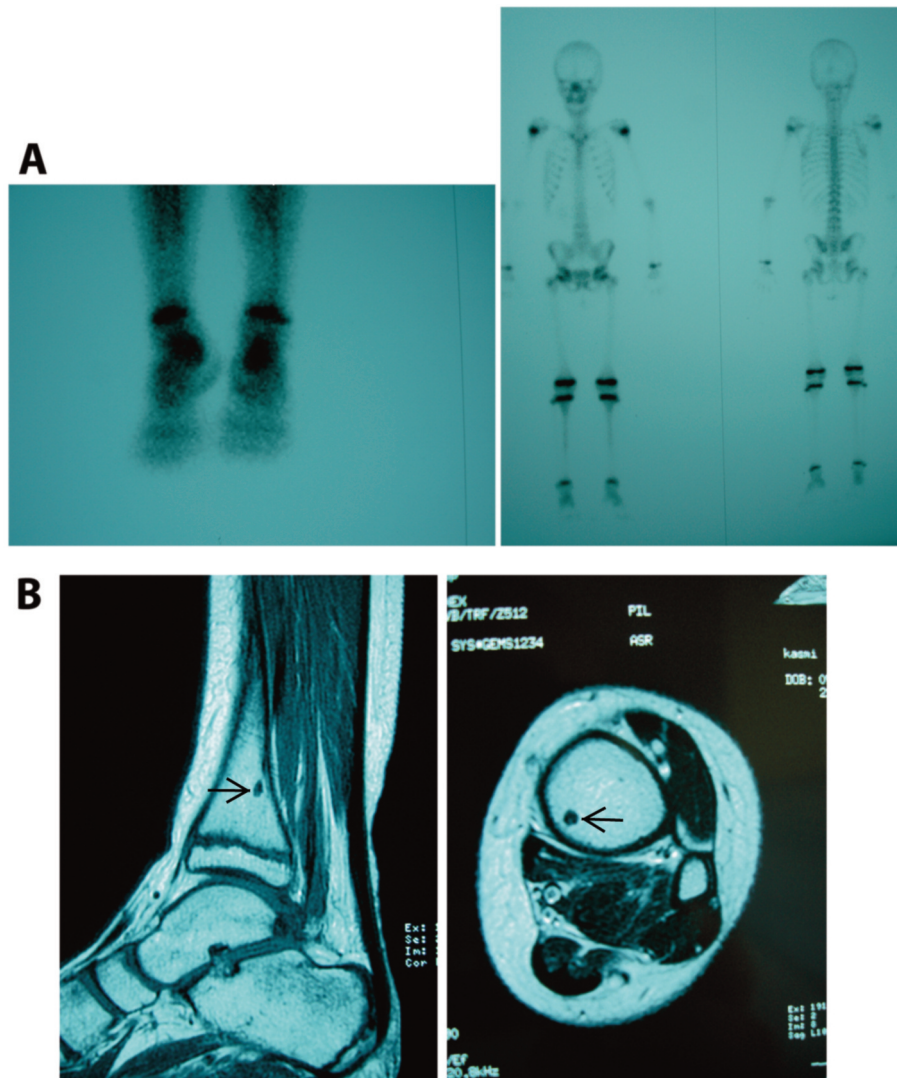


Figure 2. A. Bone lesions exhibited no increased radioisotope uptake during the three phases of bone scanning with Tc^{99m}. B. MRI appearance of the bone lesion.

lesions along with the skin findings set the diagnosis of Buschke-Ollendorff syndrome.

The syndrome, referring to our patient, was not associated with any hearing disorders or any other skeletal anomalies. Unfortunately, no genetic testing was performed due to limited resources.

Commentary

Buschke-Ollendorff syndrome (BOS) was first described by Buschke and Ollendorff in 1928 in a 41-year-old woman¹. Around 100 cases have been reported in the literature and the syndrome is estimated to have an incidence of 1:20000. It is an autosomal dominant disease characterized by unique skin and radiographic features. Occasionally patients do not express the full phenotype with bone and skin lesions occurring independently. A heterozygous mutation in the *L3MD3* gene (also

named *MAN1*) which possibly induces loss of function has been proposed as a cause for the development of BOS. This mutation may inhibit bone morphogenetic protein (BMP) signaling pathways leading to increased extracellular matrix production and the osteopoikilosis seen in BOS². The syndrome most commonly appears in the first two decades of life although late presentation has also been reported. The cutaneous lesions consist of numerous papules of elastic or collagen connective tissue nevi representing two different patterns. The first one resembles juvenile elastoma with larger grouped yellowish nodules, sometimes forming plaques usually in an asymmetric distribution. The second one is characterized by skin coloured or light yellowish papules without follicular distribution. These are commonly smaller in size, asymptomatic, and symmetrically distributed³. Our patient developed these specific skin lesions on either side of the lower back and the upper thighs.

Histologically, connective tissue stains such as Verhoeff-van Gieson or Movat's pentachrome are performed. In most cases, an increased number of thick and interlacing elastic fibers between normal collagen ones are present. Hyperplastic collagen fibers can also be seen. No treatment is needed for skin lesions. Other dermatologic conditions to be considered in the differential diagnosis of such lesions are pseudoxanthoma elasticum, papular elastorhexis, fibroelastolytic papules of the neck, juvenile hyaline fibromatosis and familiar cutaneous collagenoma⁴.

The coexistence of cutaneous lesions, such as disseminated connective tissue nevi, and osteopoikilosis is considered as diagnostic⁴. Radiographically, well defined, round sclerotic lesions in the epiphysis and metaphysis of long bones, the pelvis and carpal or tarsal bones may be evident, are most commonly symmetrically distributed and are recognized incidentally. Osteopoikilosis may be the initial finding of the syndrome. Rarely, patients are presented with solitary sclerotic bone lesions located on the metaphysis of the long bones, which have larger dimensions than the osteopoikilotic lesions. This type of lesion was apparent in our patient while bone scan and MRI were additionally performed for better evaluation. Differential diagnosis of such bone lesions include tuberous sclerosis, osteopathia striata, melorheostosis, osteoid osteoma or bone sclerotic metastatic disease. In particular, osteoid osteoma, is common in this age group and when it is detected intramedullary or in small bones it is difficult to be assessed with radiography alone. Bone scan provides a valuable tool since it is typically 'cold' in BOS.

Buschke-Ollendorf syndrome has been associated with hearing disorders such as otosclerosis, congenital spinal stenosis, craniosynostosis and nail patella syndrome⁵. None of these conditions was present in our patient.

When such an entity is suspected, a team approach is valuable to set an accurate diagnosis. A pediatrician most commonly encounters the patient first, due to skin lesions. In case of appropriate histology findings an orthopaedic surgeon consulta-

tion should be asked to assess possible bone lesions.

BOS is a benign condition with an excellent prognosis in general, if the only findings include disseminated nevi and osteopoikilosis. Since it is believed to be inherited in an autosomal dominant manner, it must be explained to the parents that they have a 50% possibility of their child develop this condition. They should also be informed about the possible incomplete penetrance of the syndrome leading to different phenotype expression. Clinical awareness of this entity is vital in order to avoid anxiety and costly clinical investigations. The spotty appearance of bone lesions may be misdiagnosed as osteoblastic metastases so the patients and parents must be reassured that their child is going to have a normal life. It should also be emphasized that these lesions would be evident in radiographs so that they would not be misinterpreted in the future. In our case the child and family were informed that the disease is not associated with increased morbidity and mortality and that a normal lifespan is to be expected for their child. Finally, no activity restriction was ordered as physical exercise is of particular value for the growing skeleton.

References

1. Buschke A, Ollendorff H. Ein Fall von dermatofibrosis lenticularis disseminata und Osteopathia condensans disseminata. *Derm Wochenschr* 1928;86:257-262.
2. Schena D, Germi L, Zamperetti MR, et al. Buschke-Ollendorff syndrome. *Int J Dermatol* 2008;47:1159-1161.
3. Hassikou H, Tabache F, Safi S, et al. Buschke-Ollendorff syndrome. *Joint Bone Spine* 2008;75(2):212-214.
4. Assmann A, Mandt N, Geilen CC, et al. Buschke-Ollendorff syndrome - differential diagnosis of disseminated connective tissue lesions. *Eur J Dermatol* 2001;11:576-579.
5. Schnur RE, Grace K, Herzberg A. Buschke-Ollendorff syndrome, otosclerosis and congenital spinal stenosis. *Pediatr Dermatol* 1994;11(1):31-4.

Questions

1. In the diagnostic work up of Buschke-Ollendorff syndrome which of the following is true?
 - A. Bone lesions do not have increased radioisotope uptake.
 - B. Sclerotic round or oval lesions are distributed asymmetrically.
 - C. Genetic testing is the gold standard for diagnosis.

Critique

The characteristic bone lesions of Buschke-Ollendorff syndrome are "cold" by scintigraphy. The 'spotty' osteopoikilotic lesions are distributed in a symmetric way and help differentiate this syndrome from bone metastases. Genetic testing may reveal loss of function mutations in the LEM domain

containing 3(LEMD3) gene but it is not necessary for an accurate diagnosis.

The correct answer is A.

2. Which of the following statements regarding Buschke-Ollendorff syndrome is false?
 - A. A mutation in the LEMD3 gene has been implicated in the development of BOS.
 - B. Hearing disorders have been associated with the syndrome.
 - C. Incomplete penetrance may occur.
 - D. Once diagnosed, severe activity restrictions are ordered by the physician.

Critique

A loss of function mutation in the LEMD3(or MAN1) gene has been reported as a possible cause of the syndrome and hearing impairment due to otosclerosis has also been linked. BOS is a rare autosomic dominant syndrome but patients may express different phenotypes due to incomplete penetrance. The most important statement about this syndrome is that it consists a benign condition, no activity restriction should be prescribed and a normal lifespan is expected for these patients. The correct answer is D.