

Can local muscles augment stability in the hip? A narrative literature review

T.H. Retchford^{1,2}, K.M. Crossley³, A. Grimaldi⁴, J.L. Kemp³, S.M. Cowan¹

¹Melbourne Physiotherapy School, University of Melbourne, Melbourne, Victoria, Australia; ²School of Community Health, Charles Sturt University, Albury, New South Wales, Australia; ³Division of Physiotherapy, School of Health and Rehabilitation Sciences, The University of Queensland, Brisbane, Australia; ⁴Physiotec Physiotherapy, Brisbane, Queensland, Australia

Abstract

Hip pain and dysfunction are increasingly recognised as important causes of morbidity in younger and older adults. Pathology compromising the passive stability of the hip joint, including acetabular labral injury, may lead to increased femoral head translation, greater joint contact pressures and ultimately degenerative hip disease. Activation of hip muscles may play an important role in augmenting the stability in the normal and the passively unstable hip. Research at other joints suggests that the local, rather than global, muscles are well suited to provide subtle joint compression, limiting translation, with minimal metabolic cost. Based on the known characteristics of local muscles and the limited research available on hip muscles, it is proposed that the local hip muscles; quadratus femoris, gluteus minimus, gemelli, obturator internus and externus, iliocapsularis and the deep fibres of iliopsoas, may be primary stabilisers of the hip joint. Interventions aimed at restoring isolated neuromuscular function of the primary hip stabilisers may be considered when treating people with passive hip instability prior to commencing global muscle rehabilitation. Finally, further research is needed to investigate the potential association between function of the hip muscles (including muscles likely to have a role in stabilising the hip) and hip pathology affecting hip stability such as acetabular labral lesions.

Keywords: Hip Joint, Hip Instability, Hip Muscle Control, Deep Hip External Rotator Muscles, Rehabilitation

Introduction

Our understanding of hip pathology, particularly degenerative hip pathology, is increasing¹. There is growing evidence that pathology affecting the hip joint's passive stability, such as acetabular labral tears, can progress to degenerative hip pathology²⁻⁵. Improving the active control of hip muscles in people with hip pathology and compromised joint stability may be the key to optimising joint loads and function, alleviating pain, and potentially even slowing the progression of hip disease.

Joint stability refers to the resistance that musculoskeletal tissues provide at a joint and is the product of contributions from passive, active and neural subsystems. Joint instability

may result from a deficit of one or more of these subsystems and lead to excessive joint translation and subsequent joint overload if the other subsystems cannot compensate⁶⁻¹¹. Hip joint instability was previously thought to be rare and usually associated with trauma¹²⁻¹⁴, or developmental bony abnormalities such as acetabular dysplasia. Whilst the hip joint is considered to be stable due to its bony architecture and strong capsuloligamentous restraints, evidence suggests that deficits in the acetabular labrum and iliofemoral ligaments may lead to increased femoral head translation¹⁶⁻¹⁸ and possibly to early degenerative hip pathology³. Although surgical techniques can be used to help improve symptoms and joint function¹⁹, there is currently little evidence that surgery in people with hip joint instability alters the progression to degenerative hip disease.

Capsuloligamentous laxity may be generalised or focal. Generalised laxity is associated with connective tissue disorders whilst focal laxity may result from an acute injury or from repetitive weight bearing rotational forces overloading specific parts of the capsuloligamentous system. Sporting activities involving repeated axial loading and rotation, such as gymnastics, football, tennis, ballet, martial arts, and golf may influence the development of focal laxity. Active stability of the hip joint

The authors have no conflict of interest.

Corresponding author: Mr Tim Retchford, School of Community Health, Charles Sturt University, Table Top Road, Thurgoona, NSW 2640 Australia
E-mail: tretchford@csu.edu.au

Edited by: S. Warden
Accepted 29 November 2012

from tension in hip muscles may augment passive stability in the normal and structurally abnormal hip¹⁰. Despite this likely important role, little is known about what muscle or muscle synergies are involved or if hip pathology has an influence on hip muscle function.

It is theorised that in the human body two muscular systems exist; local and global⁸. Local muscles are thought to be important in joint stability by acting close to the joint axis, thereby providing predominantly joint compression rather than torque, and having the ability to stiffen the joint by virtue of their extensive attachments to key passive elements of the joint. In contrast, global muscles are more superficial muscles that can generate greater torque at joints as a result of their larger physiological cross sectional area (PCSA) and greater moment arm. There is considerable research investigating muscle function and pathological muscle dysfunction at the lumbar spine, cervical spine³⁸, knee and pelvis⁴¹. This research has identified local muscle dysfunction in people with pain and pathology and that specific muscular retraining can restore muscle function at these joints. Currently, there is a paucity of literature investigating individual hip muscle function, or the association between hip pathology and dysfunction of the active hip stabilisers. Furthermore, with the exception of one study⁴², all research investigating links between hip pathology and muscle function has studied older populations suffering from osteoarthritis (OA) of the hip⁴³⁻⁴⁷. A greater understanding of the relationship between hip muscle function and hip joint stability may enhance the specificity of exercise therapy interventions with potential to improve treatment outcomes. Therefore the aim of this study was to review the available literature relating to the role the hip muscles may play in the active stability of the hip.

Methodology

Literature examining hip musculature and active stability and the possible association between hip pathology and muscle dysfunction was retrieved. In addition, literature pertaining to neuromuscular function at other joints was also retrieved to provide a broad understanding of the relationship with joint pathology. The literature search was conducted in MEDLINE (PubMed) using search terms *hip, joint, muscle, joint protection, stability, instability, quadratus femoris, gluteus medius, gemelli, obturator externus, obturator internus, piriformis, gluteus medius, gluteus maximus, pectineus, adductors, hamstrings, hip rotator cuff, lumbar spine, shoulder, knee, cervical spine, feed-forward mechanism, postural adjustments, motor control, muscle control, Real Time Ultrasound (RTUS), electromyography (EMG), Computer tomography (CT) and Magnetic Resonance Imaging (MRI)*. The reference lists of the articles were then hand searched to retrieve articles that were not identified with the computer search.

Contributors to passive hip stability and instability

The hip comprises a multiaxial ball and socket joint with six degrees of freedom⁴⁸, and is important in load transference



Copyright © 2012 McGraw-Hill Australia

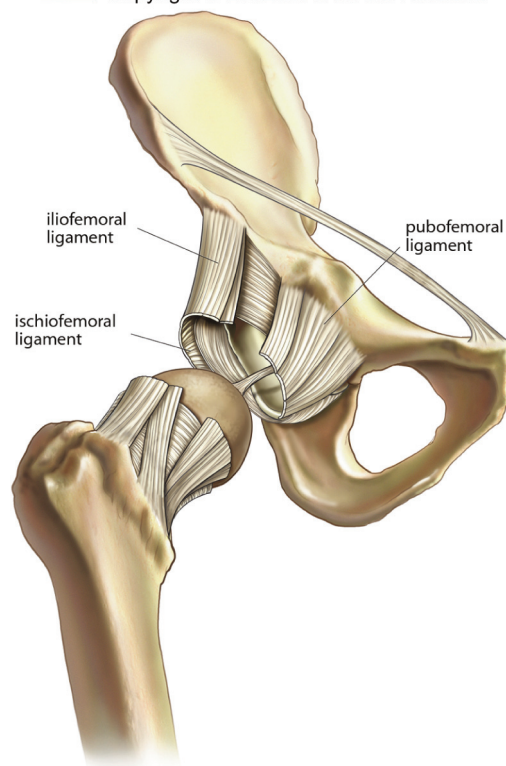


Figure 1. Capsular ligaments of the hip.

during functional activities involving both the lower and upper limbs⁴. During weight bearing activities (e.g. running), the hip is subjected to loads many times greater than body weight⁴⁹. To maintain passive stability, the hip relies on ideal bony structure, normally formed labrum and intact and ideal capsuloligamentous support. Based on modelling studies, deficits in these passive structures may lead to increased femoral head translation, or shearing forces¹⁶⁻¹⁸. It is proposed that increased shearing force of the hip joint may be associated with pathology of passive soft tissue joint restraints and subsequent pathology of joint cartilage (Figure 3).

Bony structure

The hip joint is formed by the articulation between the femoral head and the acetabulum¹⁴. The acetabulum is formed by the union of the ischium, ilium, and pubis. Only the periphery of the acetabulum articulates with the femoral head⁴⁸. Although the hip joint is considered congruent, the large femoral head has considerably more articular area compared to the acetabulum. As a result, during stance, parts of the anterior and superior articular cartilage of the femoral head remain exposed⁴⁸. This allows for greater mobility into hip flexion but also increases the reliance on anterior soft tissues for stability¹³.

Bony abnormalities resulting in reduced congruence between the femoral head and acetabulum (e.g. Developmental

dysplasia of the hip (DDH)) may lead to passive hip instability and increased reliance on surrounding soft tissue structures, particularly the anterior capsulolabral structures. Over time this increased stress may lead to fatigue failure of the acetabular labrum and subsequent chondropathy. Although this theory has not been directly studied, there is evidence suggesting increased severity⁵³ and high frequencies of labral lesions with DDH and a strong association between DDH and the development of early OA.

Other bony abnormalities such as those seen in FAI (Femoro-Acetabular Impingement - abnormal morphology of the acetabulum, femoral head or neck), have been shown to be associated with an increased risk of acetabular labral pathology and hip OA⁵⁹. This in itself may result in the development of hip instability⁵⁰. In addition, a link between posterior hip instability and FAI has recently been made, the authors proposing that as the hip reaches end range prematurely in flexion and internal rotation, the femoral head is levered against the posterior joint structures, and may result in subluxation with only low velocity force⁶².

Capsule and ligaments

The hip capsule attaches to the periphery of the acetabulum and acetabular labrum and extends down to the femoral neck⁴⁸ (Figure 1). Its fibres are aligned in a circumferential manner and are considered to provide significant passive stability to the hip joint. The capsule is further reinforced by strong extra-capsular ligaments; the iliofemoral, pubofemoral and ischiofemoral ligaments. In addition to the extra-capsular ligaments, passive hip stability may also be augmented by the intra-articular ligamentum teres. The ligamentum teres is taut in external rotation of the hip and may undergo compensatory hypertrophy in passively unstable dysplastic or labral deficient hips. In addition ligamentum teres contains free nerve endings⁶⁴ and attaches to the transverse acetabular ligament and thus the acetabular labrum⁶³, suggesting a proprioceptive role.

Capsuloligamentous laxity may be generalised or focal. Generalised laxity is associated with hypermobility syndromes and often has an underlying connective tissue disorder. It is speculated that focal laxity may arise from acute high-force trauma or repetitive overload of specific areas of the capsuloligamentous complex. People who compete in sports that require repetitive weight bearing combined with hip rotation towards, or at, the limit of normal physiological movement, such as golf, tennis and football, are reported to be more likely than inactive people to develop laxity in the capsuloligamentous system of the hip, particularly in the iliofemoral ligament. In addition, evidence of focal ligamentous instability when passive instability exists is provided by a cadaveric study of fifteen male hips. The authors noted a significant increase in hip external rotation and femoral head translation after sectioning the iliofemoral ligament, suggesting the ligament may have a significant stabilising role in the hip¹⁷. Furthermore, the proposed relationship between capsuloligamentous laxity, generalised or focal, capsular redundancy and labral lesions, particularly in active people has been highlighted in a number of review papers.

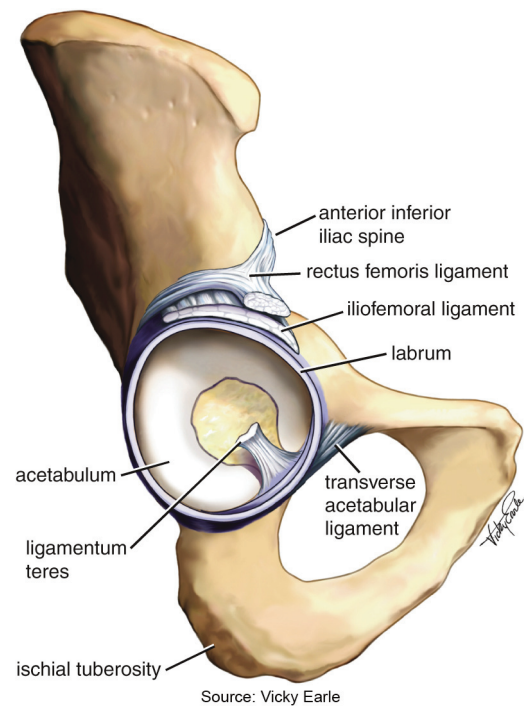


Figure 2. Transverse acetabular ligament, acetabular labrum, and ligamentum teres (resected). © McGraw-Hill Education Australia, 2012.

Acetabular Labrum

The acetabular labrum is a fibrocartilagenous extension to the rim of the acetabulum (Figure 2). While its function is not fully understood, it is considered important in improving joint congruity (increasing joint contact area by 25-28%), helping contain the femoral head in extremes of range and enhancing joint proprioception. In addition, the acetabular labrum and the inferiorly placed transverse acetabular ligament are thought to have an important role acting as a seal, limiting fluid movement in and out of the intra-articular space⁶⁷. This sealing mechanism could potentially help hydraulically distribute load evenly across the articular surfaces of the hip, thereby reducing direct hyaline cartilage contact. This sealing mechanism may also help maintain a partial vacuum in the joint, further contributing to passive stability⁴⁸. Biomechanical modelling studies suggest that in hip flexion, atmospheric pressure plays a greater joint stability role than the capsuloligamentous structures⁶⁸.

Disruption of the acetabular labrum is thought to “break the seal” of the hip joint and lead to increased femoral head translation¹⁶⁻¹⁸, greater contact pressure of the femoral head against the acetabulum, and subsequent pathology of joint cartilage³. However, due to the difficulties associated with measuring intra-articular pressure *in vivo*, this theory has not been proven. Key risk factors for labral pathology are capsuloligamentous laxity and bony abnormalities, particularly DDH and FAI. Based on review papers, it is proposed that hip joint laxity can compromise the ability of the labrum to provide adequate joint

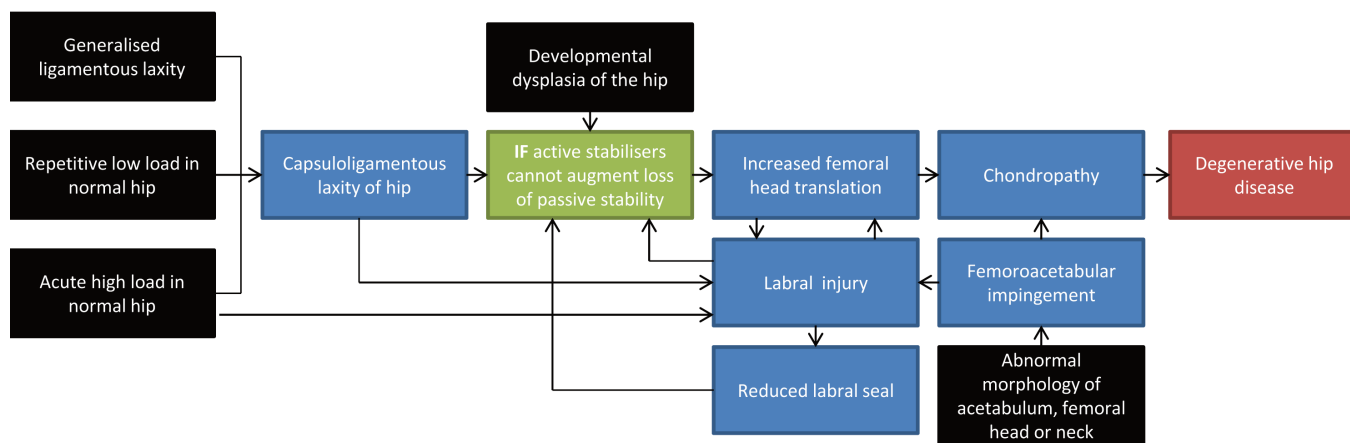


Figure 3. Proposed mechanisms for the development of degenerative hip disease as a result of multi-factorial instability. The black boxes represent the major risk factors. © McGraw-Hill Education Australia, 2012.

protection and may allow excessive femoral head translation, potentially leading to abnormal labral loading and subsequent pathology⁵¹. The link between bony abnormalities and labral pathology has been previously discussed.

Overview of muscle function, joint function and pathology

Studies on muscle function, joint function and pathology have primarily focussed on the lumbar spine, pelvis, knee and cervical spine. To date little is known of the role of the muscles acting at the hip joint and even less is known of their association with hip pathology. Knowledge of muscle function at other joints, and its association with pain or pathology may help inform understanding of hip stability and appropriate rehabilitative strategies.

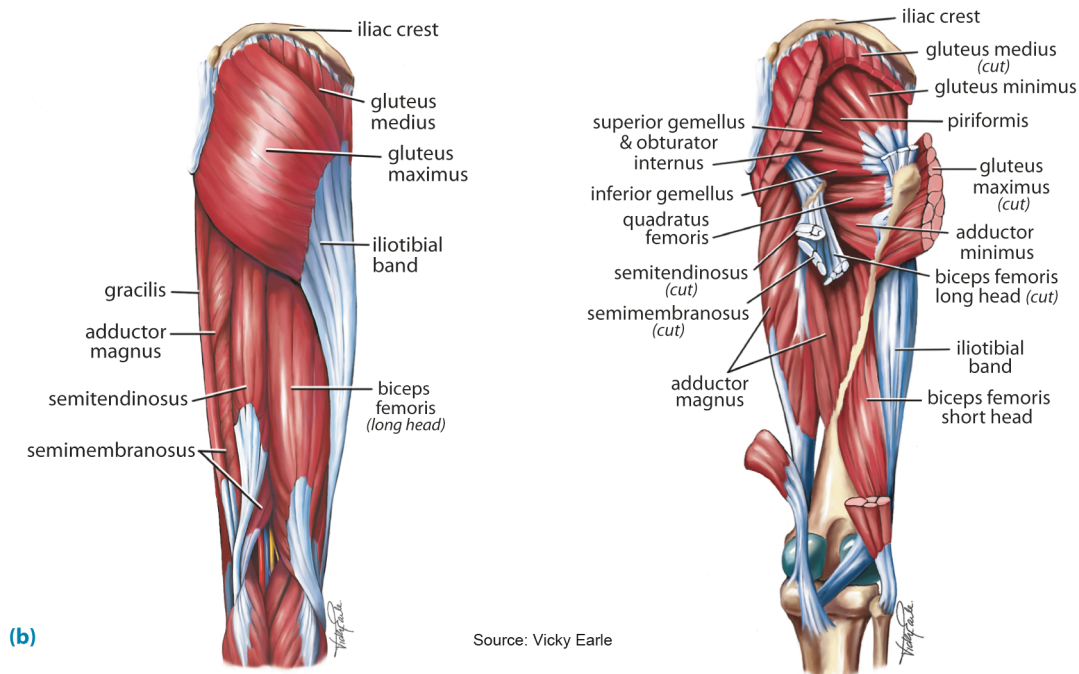
Panjabi⁶ proposed a model of joint stability for the lumbar spine involving the coordinated interaction between the passive, neural and active subsystems. He suggested that joint instability could occur with deficits in one or more of these subsystems, resulting in excessive motion and overload to joint structures if the other subsystems cannot compensate⁹. Particular muscles which form part of the active subsystem are biomechanically and physiologically well placed to provide joint protection with limited metabolic cost⁷². Although controversy exists, the weight of evidence suggests that local muscles rather than global muscles are preferentially suited to joint protection at the lumbar³⁷ and cervical spines⁷³, shoulder joint⁷⁴ and pelvis³⁶. The properties of these local muscles are discussed below.

Local muscles, such as lumbar and cervical multifidus, are predominantly composed of Type I slow twitch muscle fibres making them fatigue resistant and well suited to tonic muscle contraction; thus being ideal for postural control⁷⁵⁻⁷⁷. Fibre type gradients exist with type I fibres typically occupying deep and

type II occupying more superficial regions. *In vivo* studies have demonstrated differential activity of deep and superficial fibres of lumbar multifidus in response to functional movement and provided evidence that deep fibres have a significant stabilising role, possibly through exertion of compressive forces with minimal associated torque, whilst superficial fibres contribute primarily to joint orientation⁷². Moseley et al.⁷² theorised that the deeper fibres are anatomically and biomechanically more suited to metabolically efficient stability by virtue of their proximity to the joint's centre of rotation whilst more superficial fibres, owing to their larger CSA and moment arms, have greater torque generating capacity. At the shoulder, the rotator cuff muscles are thought to be ideally aligned to provide a net compressive force on the glenohumeral joint irrespective of shoulder position⁷⁹, whilst the transverses abdominis, owing to its transversely oriented muscle fibres, is reported to significantly increase joint compression in the sacroiliac joints³⁶.

It is rare that individual muscles act in isolation. In most instances muscle synergies exist²³. Co-contraction of muscle groups, particularly agonists and antagonists, is thought to enhance joint stiffness⁸⁰. Local muscle synergies have been described at the lumbar spine³⁵, cervical spine⁷³ and shoulder joint⁷⁴. Contractions of the local muscles are considered a feed-forward strategy by the nervous system, preparing, and thus stabilizing and protecting the joint or joints for the perturbation caused by limb movement. This hypothesis is formed on the basis that these postural adjustments occur before feedback is available⁸¹ and in advance of a limb movement⁴⁰.

Induced pain studies in the lumbar spine³⁰, and cross-sectional studies of the sacroiliac joint⁴¹, the cervical spine³⁸, and knee joint³⁹ suggest that pain alters normal feed-forward postural adjustments. Pain can also cause selective and rapid atrophy of the local muscles in the lumbar spine in response to lower back pain (LBP)²⁷ and experimental disc or nerve root injury²⁹. The underlying mechanism is unclear. The rapid onset



(b)

Source: Vicky Earle

Figure 4. Superficial (left) and deep (right) muscles around the hip.

may be more suggestive of pain inhibition rather than disuse atrophy²⁷. Global muscles are also affected by joint pain, with evidence of increased activation, which may be a compensation for local muscle dysfunction.

Studies have shown that exercise therapy targeted specifically at the local stabilising muscles can improve function, reduce pain, restore the normal feed-forward response and reduce recurrence of pain in the knee⁴⁰, cervical spine⁸⁴, and the lumbar spine^{24,81,85,86} in symptomatic individuals. Specific isolated local muscle retraining is suggested to be more effective in stabilising joints than global muscle bracing³⁶, and may lead to immediate alterations in feed-forward postural adjustments in symptomatic people⁸¹. Interventions targeting isolated tonic activation of the local muscles were found to be associated with earlier feed-forward postural activations, whereas non-specific training involving contraction of local and global muscles resulted in delayed local muscle activation. Once selective local muscle function has been restored, the use of exercises that simultaneously challenge the local and global muscles has been advocated.

Review of muscle function at the hip joint

Currently, it is unclear which muscle synergies have potential to stabilise the femoral head within the acetabulum. This is largely due to the inherent difficulties with measuring joint stability and muscle forces *in vivo*. The following review discusses what is known about individual muscles acting at the hip and explores their potential role in active joint stability. It

is based on electromyography, modelling, cadaveric studies, MRI and RTUS studies and strongly guided by recent studies investigating the line of force⁸⁷ and muscle morphology of the hip muscles⁸⁸. The primary role of muscles, local or global, is considered to be influenced by multiple factors. It is speculated, however, that muscle architecture (PCSA relative to fibre length) and lines of action are perhaps the most important features in determining primary muscle roles. Muscles that can generate large forces over small changes in muscle length and muscles that have lines of forces predominately creating joint compression could be considered to be primary active stabilisers. A number of muscles impact on the hip. However, the focus of the review is on the deeper muscles of the hip due to their potential stability role and the abductors of the hip due to information available that suggests this muscle group is closely associated with joint loading patterns.

Quadratus femoris, obturator internus and externus and gemelli

The deep external rotators (quadratus femoris, obturator internus and externus and the gemelli) have been proposed as key active stabilisers of the hip and, along with the internally rotating gluteus minimus, are often described as the “rotator cuff” of the hip. Previous research on these muscles has been limited to anatomical modelling studies and descriptive cadaver studies⁹⁰⁻⁹³. The quadratus femoris, gemelli and obturator externus and internus are described as external rotators of the hip⁴⁸, however their rotational force producing capacity, par-

ticularly in the weight bearing leg, is likely to be minimal given their small PCSA and moment arms²². These muscles do however have a favourable ratio between PCSA and fibre length, potentially making them suited to stabilising the femoral head in the acetabulum. Ward⁸⁸ speculates that the deep external rotators may play a role in modulating hip joint stiffness and providing subtle positional adjustments to the hip joint. Modelling studies suggest that the deep external rotators, with the exception of piriformis, have a nearly horizontal line of force, which is advantageous for producing external rotation, but perhaps more importantly, compression of the joint surfaces⁸⁷. As such, their morphology and proposed role is very much analogous to the rotator cuff muscles of the shoulder, particularly infraspinatus and teres minor⁸⁷.

Indirect evidence of the stabilising role of these muscles comes from studies showing increased rate of prosthetic dislocation and functional deficits following resection of the external rotator muscles with posterior surgical approach⁹⁴. When the external rotators and capsule were spared on a posterior approach using a capsular-enhanced repair, dislocation rates dropped dramatically.

Further indirect evidence of the dynamic stabilising role of quadratus femoris comes from a bed rest study by Miokovic et al.⁹⁷ who demonstrated significant preferential atrophy of the quadratus femoris muscle when investigating the effects of unloading on the postero-lateral hip muscles in 24 male subjects. Interestingly, the other deep external rotators studied (obturator internus and externus) did not demonstrate significant changes in muscle size after sixty days of bed rest. Previous bed rest studies have demonstrated preferential atrophy of the local stabilising muscles when investigating the muscles of the trunk with preservation of global muscle size²⁵.

To date, no human studies have investigated the fibre types of the hip cuff muscles. However, several animal studies have reported high proportions of slow twitch fibres in hip cuff muscles (up to 69.9% in quadratus femoris of mice). It is surmised that this high percentage of slow twitch fibres may imply a high spindle density and therefore an important proprioceptive role at the hip⁹⁸.

The lack of information on the deep hip external rotator muscles, particularly EMG data, may be explained by the depth of the muscles and their proximity to the sciatic nerve²². While RTUS and MRI studies may provide a pathway to greater understanding of deeper muscles, no studies have investigated these muscles in symptomatic and asymptomatic individuals.

Iliocapsularis

Iliocapsularis is a muscle not well described in anatomical texts. Ward et al.¹⁰⁰ described the muscle as originating from the anteromedial hip capsule as well as the inferior border of the anterior inferior iliac spine, inserting just distal to the lesser trochanter, based on observations of 20 human cadavers. Iliocapsularis' extensive attachments to the hip capsule may provide potential to tighten the anterior aspect of the capsule, enhancing joint stability. An MRI study by Babst et al.¹⁰¹ reported greater cross sectional area, greater partial volume and

less fatty infiltrate of iliocapsularis muscles of subjects with hip dysplasia compared to subjects with excessive acetabular coverage. The findings suggest that hypertrophy of iliocapsularis may represent a compensatory strategy to improve active hip joint stability in the presence of passive hip instability¹⁰⁰.

Piriformis

The piriformis may be important in stability of the hip with evidence of lower dislocation rates when the piriformis is preserved following insertion of a prosthetic hip via a posterior approach. This may imply an important role in stabilising the hip, however it should be noted that these studies looked at piriformis in conjunction with quadratus femoris⁹⁴, and obturator internus⁸⁹. Piriformis is most active in resisted external rotation of the hip¹⁰². Like the other deep external rotators, the piriformis muscle has a high ratio of PCSA: fibre length suggesting a potential stability role, however unlike the other external rotators of the hip, the line of force of the piriformis muscle is not as favourable to enhance joint compression⁸⁷.

Gluteus minimus

Gluteus minimus, the deepest part of the abductor synergy, is an abductor, rotator and flexor of the hip¹⁰³. However, its primary function is considered to be as a stabiliser of the hip and pelvis¹⁰³⁻¹⁰⁵. Its fibres run parallel to the neck of the femur¹⁰⁴, and it has attachments to the superior aspect of the capsule¹⁰⁶, supporting the contention that gluteus minimus is an important stabiliser of the femoral head in the acetabulum. A cadaveric study by Beck et al.¹⁰³ of 16 hips found the gluteus minimus had extensive attachments to the hip joint capsule. Gluteus minimus may therefore be important in stabilising the hip by being able to modulate joint capsule stiffness; it may also help prevent anterior dislocation and superomedial migration of the femoral head, as well as providing a proprioceptive role. A recent fine wire EMG study has provided support for the role of the gluteus minimus as a stabiliser in their demonstration that the anterior portion of gluteus minimus is active in both prone hip extension and in late stance phase, acting presumably to provide anterior support to the joint, rather than as a hip extensor for which it has no moment arm¹⁰⁷.

Gluteus medius

Gluteus medius is the primary abductor of the hip and important stabiliser of the pelvis and hip, preventing the pelvis from dropping in single leg stance. It has three segments; anterior, posterior, middle or superficial. Each segment is separately innervated and has unique fibre orientation. Electromyographic analysis suggests that the amplitude of activity in any of the segments is highly dependent upon the task and gluteus medius activation is not always consistent across the segments¹⁰⁹. Based on anatomical and surface electromyographic studies, Gottschalk et al.¹⁰⁴ propose that during gait the posterior portion of gluteus medius is an important stabiliser of the femoral head in the acetabulum whilst the middle subdivision helps initiate hip abduction and the anterior subdivision contracts to cause pelvic rotation. Other gait studies

suggest that the gluteus medius plays an important stabilising role of the pelvis on the hip by contracting prior to and after foot contact to prevent adduction of the hip. This activity does not seem to change with increased speed. In contrast to Gottschalk et al.¹⁰⁴ these studies did not individually test the three subdivisions of gluteus medius. A fine wire EMG study investigating the activation of the three segments of gluteus medius during non weight bearing hip movements, found the anterior portion of the muscle to be highly active during hip extension, perhaps suggesting a stability role in this position to minimise anterior femoral head translation¹¹⁰. Anatomical modelling studies indicate that gluteus medius may act as a hip stabiliser on the basis of a high ratio of PCSA: fibre length, however its large moment arm for abduction makes it better suited to produce force, advantageous for stabilising the pelvis in weight bearing, rather than optimal positioning of the femoral head in the acetabulum during functional activities.

Iliopsoas

Iliopsoas has two main portions, psoas major and iliacus, which are separately innervated. Both are active throughout hip flexion. Psoas major has been found to have a greater percentage of fast twitch than slow twitch muscle fibres, particularly in its caudal portion based on muscle biopsies of 15 male subjects⁷⁸, whereas an animal histology study suggested iliacus may contain a large proportion of slow twitch fibres⁹⁸. A fine wire EMG study by Andersson et al.¹¹⁴ investigating 11 subjects, supports the role of iliacus as a stabiliser of the hip, particularly in late stance phase of gait. Lewis et al.¹¹⁵ surmised that the iliacus and psoas muscles may play a role similar to that of the rotator cuff muscles at the shoulder by being able to influence joint stability not only by its insertion but also by tension in musculotendinous units as they pass over the anterior aspect of the hip joint.

A prolonged bed rest study by Mendis et al.¹¹⁶ investigated the effect on the anterior hip muscles of 8 weeks of bed rest, with results showing reduced CSA of the deep fibres of iliopsoas at the level of the head of femur, suggesting preferential atrophy.

Discussion

Active hip stability is likely to be primarily modulated by the deep local muscles

If the passive stability mechanisms of the hip are inadequate, due to local pathology or insufficiency, the muscular system will be needed to augment stability. The local muscles of the hip including gluteus medius, quadratus femoris, gemelli, obturator internus and externus, iliocapsularis and possibly the deep fibres of iliopsoas are anatomically, biomechanically and physiologically well suited to provide dynamic stabilisation of the femoral head in the acetabulum, helping reduce shearing forces on the joint. These muscles share many of the characteristics of other local muscles of the lumbar spine, pelvis, shoulder and knee. Although most have relatively small PCSA, they have short muscle fibre lengths and are therefore able to produce significant forces over small changes

in muscle length. They also have advantageous lines of force to provide compression of the head of the femur in the acetabulum. They may also contain predominantly slow twitch muscle fibres, making them suited to tonic contractions and providing fatigue resistance and have direct capsular attachments, suggesting a significant proprioceptive role.

Co-contraction of local muscles is theorised to occur in the lumbar spine, shoulder and knee. It is plausible that local muscles act with synergy to provide hip joint stability, perhaps with the coordinated contraction of the deep internal and external rotators.

More research is needed to elucidate the effect of pathology on these local muscles. Many of the seminal articles investigating the function and dysfunction of muscles such as transversus abdominis, lumbar multifidus⁷², and gluteus medius¹¹⁷ have used fine wire EMG to demonstrate changes in the timing of the muscle contractions. Unfortunately the inaccessibility of the deeper stabilising muscles, particularly those lying posterior to the hip joint, makes them difficult to assess. Although fine wire EMG studies are likely to give the most definitive data, new technologies such as RTUS and dynamic MRI, may provide a less invasive method of collecting data.

Future directions in hip rehabilitation

Hip muscle strengthening exercises, particularly hip abductor strengthening, are the most commonly prescribed intervention by physiotherapists in patients with hip pain but current evidence suggests that joint stability may be enhanced via retraining of deep hip stabilisers. Although most clinicians advocate for the use of functional rehabilitation exercises, there is some evidence to suggest that this alone is inadequate for the effective retraining of normal feed-forward postural activity⁸¹. Much akin to the current rationale of strengthening the local muscles at the lumbar spine and pelvis, cervical spine, and shoulder joint prior to addressing the more superficial global muscles, it could be argued that effective therapeutic exercise programs for the pathological hip should initially target local stabilising muscles using low load tonic exercises. Specific exercises for retraining the local muscles of the hip are commonly started in positions of low postural load such as prone or sidelying. The patient can be taught to monitor their motor performance by careful palpation. In the case of a patient presenting with concurrent aberrant lumbopelvic motor control, co-contraction of the deep hip stabilisers and lumbopelvic stabilisers can be taught. Clinically such an approach appears to be effective however there is currently no evidence to support its use as it has not been evaluated. One difficulty facing clinicians is reliably measuring the function of the local muscles of the hip. RTUS is now commonly used by physiotherapists to assess and retrain muscles of the abdominal wall and lumbar spine. This technology may prove to be a reliable and valid tool for measuring local hip muscle function and for providing feedback on motor performance whilst performing rehabilitation exercises. To date there has only been one study validating the use of RTUS for measuring the size of anterior hip muscles, with findings that this clinical tool is reliable compared to MRI¹¹⁹. More research is needed to validate the

use of RTUS as a measuring tool in other active stabilising muscles. Hand held dynamometry has been utilized to reliably determine muscle function in previous studies examining hip OA¹²⁰, FAI⁴², and groin pain¹²¹. This may provide some insight, but further research is required to elucidate tests that are more specific for assessing deep muscle function. Testing the ability to actively move into inner range, for which the deep musculature has a better lever arm, and to tonically hold an inner range contraction have previously been suggested as important motor control assessments and retraining strategies for lumbopelvic stabilisation³⁴ but these have not been well tested around the hip.

Once isolated contraction of the deep external rotator muscles is successfully achieved, progression can be made to the rehabilitation of secondary stabilisers and prime movers of the hip, particularly the gluteus maximus, initially using non-weight bearing exercises and progressing to weight bearing exercises once motor control and strength allows. Pre-activation of the deep external rotators may make these exercises more effective. Deficits in flexibility and proprioception should also be addressed at this stage. Once adequate hip muscle strength and endurance is achieved, functional and sports specific exercises can then be implemented.

Furthering our understanding of the role of muscles and muscle synergies at the hip may provide insight into the development of more specific assessment and treatment protocols, ensuring adequate hip joint stability in people with hip pain or pathology.

References

1. Wright AA, Cook C, Abbott JH. Variables associated with the progression of hip osteoarthritis: a systematic review. *Arthritis Rheum* 2009;61:925-36.
2. Reichenbach S, Leunig M, Werlen S, et al. Association between cam-type deformities and magnetic resonance imaging-detected structural hip damage: a cross-sectional study in young men. *Arthritis Rheum* 2011; 63:4023-30.
3. McCarthy JC, Noble PC, Schuck MR, Wright J, Lee J. The Role of Labral Lesions to Development of Early Degenerative Hip Disease. *Clin Orthop Relat Res* 2001; (393):25-37.
4. Nicholls RA. Intra-articular disorders of the hip in athletes. *Physical Therapy in Sport* 1994;5:17-25.
5. Hossain M, Andrew JG. Current management of femoroacetabular impingement. *Current Orthopaedics* 2008; 22:300-10.
6. Panjabi MM. The stabilizing system of the spine. Part II. Neutral zone and instability hypothesis. *J Spinal Disord* 1992;5:390-6; discussion 7.
7. van Wingerden JP, Vleeming A, Buyruk HM, Raissadat K. Stabilization of the sacroiliac joint *in vivo*: verification of muscular contribution to force closure of the pelvis. *European spine journal: official publication of the European Spine Society, the European Spinal Deformity Society, and the European Section of the Cervical Spine Research Society* 2004;13:199-205.
8. Bergmark A. Stability of the lumbar spine. A study in mechanical engineering. *Acta Orthop Scand Suppl* 1989; 230:1-54.
9. Panjabi M, Abumi K, Duranceau J, Oxland T. Spinal stability and intersegmental muscle forces. A biomechanical model. *Spine (Phila Pa 1976)* 1989;14:194-200.
10. Shu B, Safran MR. Hip instability: anatomic and clinical considerations of traumatic and atraumatic instability. *Clin Sports Med* 2011;30:349-67.
11. O'Sullivan PB. Lumbar segmental 'instability': clinical presentation and specific stabilizing exercise management. *Man Ther* 2000;5:2-12.
12. Bellabarba C, Sheinkop MB, Kuo KN. Idiopathic hip instability. An unrecognized cause of coxa saltans in the adult. *Clin Orthop Relat Res* 1998:261-71.
13. Boykin RE, Anz AW, Bushnell BD, Kocher MS, Stubbs AJ, Philippon MJ. Hip instability. *J Am Acad Orthop Surg* 2011;19:340-9.
14. Shindle MK, Ranawat AS, Kelly BT. Diagnosis and management of traumatic and atraumatic hip instability in the athletic patient. *Clin Sports Med* 2006;25:309-26, ix-x.
15. McCarthy JC, Lee JA. Acetabular dysplasia: a paradigm of arthroscopic examination of chondral injuries. *Clin Orthop Relat Res* 2002:122-8.
16. Smith MV, Panchal HB, Ruberte Thiele RA, Sekiya JK. Effect of acetabular labrum tears on hip stability and labral strain in a joint compression model. *Am J Sports Med* 2011;39 Suppl:103S-10S.
17. Myers CA, Register BC, Lertwanich P, et al. Role of the acetabular labrum and the iliofemoral ligament in hip stability: an *in vitro* biplane fluoroscopy study. *Am J Sports Med* 2011;39 Suppl:85S-91S.
18. Crawford MJ, Dy CJ, Alexander JW, et al. The 2007 Frank Stinchfield Award. The biomechanics of the hip labrum and the stability of the hip. *Clin Orthop Relat Res* 2007;465:16-22.
19. Kemp JL, Collins NJ, Makdissi M, Schache AG, Machotka Z, Crossley K. Hip arthroscopy for intra-articular pathology: a systematic review of outcomes with and without femoral osteoplasty. *Br J Sports Med* 2012;46:632-43.
20. Ng VY, Arora N, Best TM, Pan X, Ellis TJ. Efficacy of surgery for femoroacetabular impingement: a systematic review. *Am J Sports Med* 2010;38:2337-45.
21. Philippon MJ, Stubbs AJ, Schenker ML, Maxwell RB, Ganz R, Leunig M. Arthroscopic management of femoroacetabular impingement: osteoplasty technique and literature review. *Am J Sports Med* 2007;35:1571-80.
22. Torry MR, Schenker ML, Martin HD, Hogoboom D, Philippon MJ. Neuromuscular hip biomechanics and pathology in the athlete. *Clin Sports Med* 2006;25:179-97, vii.
23. Kavcic N, Grenier S, McGill SM. Determining the stabilizing role of individual torso muscles during rehabilitation exercises. *Spine (Phila Pa 1976)* 2004;29:1254-65.

24. O'Sullivan PB, Twomey L, Allison GT. Altered abdominal muscle recruitment in patients with chronic back pain following a specific exercise intervention. *J Orthop Sports Phys Ther* 1998;27:114-24.
25. Hides JA, Belavy DL, Stanton W, et al. Magnetic resonance imaging assessment of trunk muscles during prolonged bed rest. *Spine (Phila Pa 1976)* 2007;32:1687-92.
26. Hides JA, Miokovic T, Belavy DL, Stanton WR, Richardson CA. Ultrasound imaging assessment of abdominal muscle function during drawing-in of the abdominal wall: an intrarater reliability study. *J Orthop Sports Phys Ther* 2007;37:480-6.
27. Hides JA, Stokes MJ, Saide M, Jull GA, Cooper DH. Evidence of lumbar multifidus muscle wasting ipsilateral to symptoms in patients with acute/subacute low back pain. *Spine (Phila Pa 1976)* 1994;19:165-72.
28. Hides JA, Wong I, Wilson SJ, Belavy DL, Richardson CA. Assessment of abdominal muscle function during a simulated unilateral weight-bearing task using ultrasound imaging. *J Orthop Sports Phys Ther* 2007;37:467-71.
29. Hodges P, Holm AK, Hansson T, Holm S. Rapid atrophy of the lumbar multifidus follows experimental disc or nerve root injury. *Spine (Phila Pa 1976)* 2006;31:2926-33.
30. Hodges PW, Moseley GL, Gabrielsson A, Gandevia SC. Experimental muscle pain changes feedforward postural responses of the trunk muscles. *Exp Brain Res* 2003; 151:262-71.
31. Hodges PW, Richardson CA. Feedforward contraction of transversus abdominis is not influenced by the direction of arm movement. *Exp Brain Res* 1997;114:362-70.
32. Hodges PW, Richardson CA. Delayed postural contraction of transversus abdominis in low back pain associated with movement of the lower limb. *J Spinal Disord* 1998;11:46-56.
33. McGill SM, Grenier S, Kavcic N, Cholewicki J. Coordination of muscle activity to assure stability of the lumbar spine. *J Electromyogr Kinesiol* 2003;13:353-9.
34. Richardson C, Hodges PW, Hides J. Therapeutic exercise for lumbopelvic stabilization : a motor control approach for the treatment and prevention of low back pain. 2nd ed. Edinburgh: Churchill Livingstone; 2004.
35. Richardson CA, Jull GA. Muscle control-pain control. What exercises would you prescribe? *Man Ther* 1995;1:2-10.
36. Richardson CA, Snijders CJ, Hides JA, Damen L, Pas MS, Storm J. The relation between the transversus abdominis muscles, sacroiliac joint mechanics, and low back pain. *Spine (Phila Pa 1976)* 2002;27:399-405.
37. Wilke HJ, Wolf S, Claes LE, Arand M, Wiesend A. Stability increase of the lumbar spine with different muscle groups. A biomechanical *in vitro* study. *Spine (Phila Pa 1976)* 1995;20:192-8.
38. Falla D, Jull G, Hodges PW. Feedforward activity of the cervical flexor muscles during voluntary arm movements is delayed in chronic neck pain. *Exp Brain Res* 2004; 157:43-8.
39. Cowan SM, Bennell KL, Hodges PW, Crossley KM, McConnell J. Delayed onset of electromyographic activity of vastus medialis obliquus relative to vastus lateralis in subjects with patellofemoral pain syndrome. *Arch Phys Med Rehabil* 2001;82:183-9.
40. Cowan SM, Bennell KL, Hodges PW, Crossley KM, McConnell J. Simultaneous feedforward recruitment of the vasti in untrained postural tasks can be restored by physical therapy. *J Orthop Res* 2003;21:553-8.
41. Hungerford B, Gilleard W, Hodges P. Evidence of altered lumbopelvic muscle recruitment in the presence of sacroiliac joint pain. *Spine (Phila Pa 1976)* 2003;28:1593-600.
42. Casartelli NC, Maffiuletti NA, Item-Glatthorn JF, et al. Hip muscle weakness in patients with symptomatic femoroacetabular impingement. *Osteoarthritis and cartilage/OARS, Osteoarthritis Research Society* 2011;19:816-21.
43. Grimaldi A, Richardson C, Stanton W, Durbridge G, Donnelly W, Hides J. The association between degenerative hip joint pathology and size of the gluteus medius, gluteus minimus and piriformis muscles. *Man Ther* 2009;14:605-10.
44. Grimaldi A, Richardson C, Durbridge G, Donnelly W, Darnell R, Hides J. The association between degenerative hip joint pathology and size of the gluteus maximus and tensor fascia lata muscles. *Man Ther* 2009;14:611-7.
45. Sims KJ, Richardson CA, Brauer SG. Investigation of hip abductor activation in subjects with clinical unilateral hip osteoarthritis. *Ann Rheum Dis* 2002;61:687-92.
46. Rasch A, Bystrom AH, Dalen N, Berg HE. Reduced muscle radiological density, cross-sectional area, and strength of major hip and knee muscles in 22 patients with hip osteoarthritis. *Acta Orthop* 2007;78:505-10.
47. Arokoski MH, Arokoski JP, Haara M, et al. Hip muscle strength and muscle cross sectional area in men with and without hip osteoarthritis. *J Rheumatol* 2002;29:2185-95.
48. Levangie PK, Norkin CC. Joint structure and function : a comprehensive analysis. 4th ed. Philadelphia, Pa.: F.A. Davis Co.; 2005.
49. Bergmann G, Graichen F, Rohlmann A. Hip joint loading during walking and running, measured in two patients. *Journal of biomechanics* 1993;26:969-90.
50. Ganz R, Parvizi J, Beck M, Leunig M, Notzli H, Siebenrock KA. Femoroacetabular impingement: a cause for osteoarthritis of the hip. *Clin Orthop Relat Res* 2003; (417):112-20.
51. Philippon MJ. The role of arthroscopic thermal capsulorrhaphy in the hip. *Clinics in sports medicine* 2001; 20:817-29.
52. Millis MB, Kim YJ. Rationale of osteotomy and related procedures for hip preservation: a review. *Clin Orthop Relat Res* 2002;(405):108-21.
53. Nepple JJ, Carlisle JC, Nunley RM, Clohisy JC. Clinical and radiographic predictors of intra-articular hip disease in arthroscopy. *Am J Sports Med* 2011;39:296-303.
54. McCarthy JC, Noble PC, Schuck MR, Wright J, Lee J. The watershed labral lesion: its relationship to early arthritis of the hip. *The Journal of arthroplasty* 2001; 16:81-7.

55. Stelzeneder D, Mamisch TC, Kress I, et al. Patterns of joint damage seen on MRI in early hip osteoarthritis due to structural hip deformities. *Osteoarthritis and cartilage/OARS, Osteoarthritis Research Society* 2012;20:661-9.
56. Gosvig KK, Jacobsen S, Sonne-Holm S, Palm H, Troelsen A. Prevalence of malformations of the hip joint and their relationship to sex, groin pain, and risk of osteoarthritis: a population-based survey. *J Bone Joint Surg Am* 2010;92:1162-9.
57. Lievense AM, Bierma-Zeinstra SM, Verhagen AP, Verhaar JA, Koes BW. Influence of hip dysplasia on the development of osteoarthritis of the hip. *Ann Rheum Dis* 2004;63:621-6.
58. Lane NE, Lin P, Christiansen L, et al. Association of mild acetabular dysplasia with an increased risk of incident hip osteoarthritis in elderly white women: the study of osteoporotic fractures. *Arthritis Rheum* 2000;43:400-4.
59. Nicholls AS, Kiran A, Pollard TC, et al. The association between hip morphology parameters and nineteen-year risk of end-stage osteoarthritis of the hip: a nested case-control study. *Arthritis and rheumatism* 2011;63:3392-400.
60. Philippon MJ, Weiss DR, Kuppersmith DA, Briggs KK, Hay CJ. Arthroscopic labral repair and treatment of femoroacetabular impingement in professional hockey players. *Am J Sports Med* 2010;38:99-104.
61. Haviv B, O'Donnell J. The incidence of total hip arthroplasty after hip arthroscopy in osteoarthritic patients. *Sports Med Arthrosc Rehabil Ther Technol* 2010;2:18.
62. Krych AJ, Thompson M, Larson CM, Byrd JW, Kelly BT. Is posterior hip instability associated with cam and pincer deformity? *Clin Orthop Relat Res* 2012;470:3390-7.
63. Rao J, Zhou YX, Villar RN. Injury to the ligamentum teres. Mechanism, findings, and results of treatment. *Clin Sports Med* 2001;20:791-9, vii.
64. Leunig M, Beck M, Stauffer E, Hertel R, Ganz R. Free nerve endings in the ligamentum capitis femoris. *Acta Orthop Scand* 2000;71:452-4.
65. Ferguson SJ, Bryant JT, Ganz R, Ito K. The acetabular labrum seal: a poroelastic finite element model. *Clin Biomech (Bristol, Avon)* 2000;15:463-8.
66. Tan V, Seldes RM, Katz MA, Freedhand AM, Klimkiewicz JJ, Fitzgerald RH, Jr. Contribution of acetabular labrum to articulating surface area and femoral head coverage in adult hip joints: an anatomic study in cadavera. *Am J Orthop (Belle Mead NJ)* 2001;30:809-12.
67. Ferguson SJ, Bryant JT, Ganz R, Ito K. An *in vitro* investigation of the acetabular labral seal in hip joint mechanics. *J Biomech* 2003;36:171-8.
68. Wingstrand H, Wingstrand A, Krantz P. Intracapsular and atmospheric pressure in the dynamics and stability of the hip. A biomechanical study. *Acta Orthop Scand* 1990; 61:231-5.
69. Ferguson SJ, Bryant JT, Ganz R, Ito K. The influence of the acetabular labrum on hip joint cartilage consolidation: a poroelastic finite element model. *J Biomech* 2000; 33:953-60.
70. Groh MM, Herrera J. A comprehensive review of hip labral tears. *Curr Rev Musculoskelet Med* 2009;2:105-17.
71. Martin RL, Enseki KR, Draovitch P, Trapuzzano T, Philippon MJ. Acetabular labral tears of the hip: examination and diagnostic challenges. *J Orthop Sports Phys Ther* 2006;36:503-15.
72. Moseley GL, Hodges PW, Gandevia SC. Deep and superficial fibers of the lumbar multifidus muscle are differentially active during voluntary arm movements. *Spine (Phila Pa 1976)* 2002;27:E29-36.
73. Mayoux-Benhamou MA, Revel M, Vallee C, Roudier R, Barbet JP, Bary F. Longus colli has a postural function on cervical curvature. *Surg Radiol Anat* 1994;16:367-71.
74. Wuelker N, Korell M, Thren K. Dynamic glenohumeral joint stability. *J Shoulder Elbow Surg* 1998;7:43-52.
75. Zhao WP, Kawaguchi Y, Matsui H, Kanamori M, Kimura T. Histochemistry and morphology of the multifidus muscle in lumbar disc herniation: comparative study between diseased and normal sides. *Spine (Phila Pa 1976)* 2000; 25:2191-9.
76. Boyd-Clark LC, Briggs CA, Galea MP. Comparative histochemical composition of muscle fibres in a pre- and a postvertebral muscle of the cervical spine. *J Anat* 2001; 199:709-16.
77. Johnson MA, Sideri G, Weightman D, Appleton D. A comparison of fibre size, fibre type constitution and spatial fibre type distribution in normal human muscle and in muscle from cases of spinal muscular atrophy and from other neuromuscular disorders. *J Neurol Sci* 1973;20:345-61.
78. Arbanas J, Klasan GS, Nikolic M, Jerkovic R, Miljanovic I, Malnar D. Fibre type composition of the human psoas major muscle with regard to the level of its origin. *J Anat* 2009;215:636-41.
79. Labriola JE, Lee TQ, Debski RE, McMahon PJ. Stability and instability of the glenohumeral joint: the role of shoulder muscles. *J Shoulder Elbow Surg* 2005;14:32S-8S.
80. Carter RR, Crago PE, Gorman PH. Nonlinear stretch reflex interaction during cocontraction. *J Neurophysiol* 1993;69:943-52.
81. Tsao H, Hodges PW. Immediate changes in feedforward postural adjustments following voluntary motor training. *Exp Brain Res* 2007;181:537-46.
82. Cholewicki J, Greene HS, Polzhofer GK, Galloway MT, Shah RA, Radebold A. Neuromuscular function in athletes following recovery from a recent acute low back injury. *J Orthop Sports Phys Ther* 2002;32:568-75.
83. Jull GA. Deep cervical flexor muscle dysfunction in whiplash. *Journal of Musculoskeletal Pain* 2000;8:143-54.
84. Jull G, Trott P, Potter H, et al. A randomized controlled trial of exercise and manipulative therapy for cervicogenic headache. *Spine (Phila Pa 1976)* 2002;27:1835-43; discussion 43.
85. O'Sullivan PB, Phytty GD, Twomey LT, Allison GT. Evaluation of specific stabilizing exercise in the treatment of chronic low back pain with radiologic diagnosis of spondylolysis or spondylolisthesis. *Spine (Phila Pa 1976)*

- 1997;22:2959-67.
86. Hides JA, Jull GA, Richardson CA. Long-term effects of specific stabilizing exercises for first-episode low back pain. *Spine (Phila Pa 1976)* 2001;26:E243-8.
 87. Neumann DA. Kinesiology of the hip: a focus on muscular actions. *J Orthop Sports Phys Ther* 2010;40:82-94.
 88. Ward SR, Winters TM, Blemker SS. The architectural design of the gluteal muscle group: implications for movement and rehabilitation. *J Orthop Sports Phys Ther* 2010;40:95-102.
 89. Pine J, Binns M, Wright P, Soames R. Piriformis and obturator internus morphology: a cadaveric study. *Clin Anat* 2011;24:70-6.
 90. Aung HH, Sakamoto H, Akita K, Sato T. Anatomical study of the obturator internus, gemelli and quadratus femoris muscles with special reference to their innervation. *Anat Rec* 2001;263:41-52.
 91. Honma S, Jun Y, Horiguchi M. The human gemelli muscles and their nerve supplies. *Kaibogaku Zasshi* 1998;73:329-35.
 92. Solomon LB, Lee YC, Callary SA, Beck M, Howie DW. Anatomy of piriformis, obturator internus and obturator externus: implications for the posterior surgical approach to the hip. *J Bone Joint Surg Br* 2010;92:1317-24.
 93. Stibbe EP. Complete Absence of the Quadratus Femoris. *J Anat* 1929;64:97.
 94. Khan RJ, Yao F, Li M, Nivbrant B, Wood D. Capsular-enhanced repair of the short external rotators after total hip arthroplasty. *J Arthroplasty* 2007;22:840-3.
 95. Hedley AK, Hendren DH, Mead LP. A posterior approach to the hip joint with complete posterior capsular and muscular repair. *The Journal of arthroplasty* 1990;5 Suppl:S57-66.
 96. White RE Jr, Forness TJ, Allman JK, Junick DW. Effect of posterior capsular repair on early dislocation in primary total hip replacement. *Clin Orthop Relat Res* 2001;163-7.
 97. Miokovic T, Armbrecht G, Felsenberg D, Belavy DL. Differential atrophy of the postero-lateral hip musculature during prolonged bedrest and the influence of exercise countermeasures. *J Appl Physiol* 2011;110:926-34.
 98. Roy RR, Kim JA, Monti RJ, Zhong H, Edgerton VR. Architectural and histochemical properties of cat hip 'cuff' muscles. *Acta Anat (Basel)* 1997;159:136-46.
 99. Hitomi Y, Kizaki T, Watanabe S, et al. Seven skeletal muscles rich in slow muscle fibers may function to sustain neutral position in the rodent hindlimb. *Comp Biochem Physiol B Biochem Mol Biol* 2005;140:45-50.
 100. Ward WT, Fleisch ID, Ganz R. Anatomy of the iliocapsularis muscle. Relevance to surgery of the hip. *Clin Orthop Relat Res* 2000;278-85.
 101. Babst D, Steppacher SD, Ganz R, Siebenrock KA, Tanast M. The iliocapsularis muscle: an important stabilizer in the dysplastic hip. *Clin Orthop Relat Res* 2011;469:1728-34.
 102. Giphart JE, Stull JD, Laprade RF, Wahoff MS, Philippon MJ. Recruitment and activity of the pectineus and piriformis muscles during hip rehabilitation exercises: an electromyography study. *Am J Sports Med* 2012;40:1654-63.
 103. Beck M, Sledge JB, Gautier E, Dora CF, Ganz R. The anatomy and function of the gluteus minimus muscle. *J Bone Joint Surg Br* 2000;82:358-63.
 104. Gottschalk F, Kourosh S, Leveau B. The functional anatomy of tensor fasciae latae and gluteus medius and minimus. *J Anat* 1989;166:179-89.
 105. Kumagai M, Shiba N, Higuchi F, Nishimura H, Inoue A. Functional evaluation of hip abductor muscles with use of magnetic resonance imaging. *J Orthop Res* 1997;15:888-93.
 106. Walters J, Solomons M, Davies J. Gluteus minimus: observations on its insertion. *J Anat* 2001;198:239-42.
 107. Semciw AI, Pizzari T, Green RA. Are there structurally unique segments within gluteus minimus and gluteus medius? An EMG investigation. in XIXth Congress of the International Society for Electrophysiology and Kinesiology ISEK Brisbane, Australia 2012.
 108. Earl JE. Gluteus Medius Activity During 3 Variations of Isometric Single-Leg Stance. *J Sport Rehabil* 2004;13:1-11.
 109. O'Sullivan K, Smith SM, Sainsbury D. Electromyographic analysis of the three subdivisions of gluteus medius during weight-bearing exercises. *Sports Med Arthrosc Rehabil Ther Technol* 2010;2:17.
 110. Semciw AI, Pizzari T, Green RA. Intramuscular EMG placement for two segments of gluteus minimus and three segments of gluteus medius with unique orientation and function. *J Sci Med Sport* 2011;14:S189.
 111. Mann RA, Moran GT, Dougherty SE. Comparative electromyography of the lower extremity in jogging, running, and sprinting. *Am J Sports Med* 1986;14:501-10.
 112. Montgomery WH 3rd, Pink M, Perry J. Electromyographic analysis of hip and knee musculature during running. *Am J Sports Med* 1994;22:272-8.
 113. Andersson E, Oddsson L, Grundstrom H, Thorstensson A. The role of the psoas and iliacus muscles for stability and movement of the lumbar spine, pelvis and hip. *Scand J Med Sci Sports* 1995;5:10-6.
 114. Andersson EA, Nilsson J, Thorstensson A. Intramuscular EMG from the hip flexor muscles during human locomotion. *Acta Physiol Scand* 1997;161:361-70.
 115. Lewis CL, Sahrman SA, Moran DW. Anterior hip joint force increases with hip extension, decreased gluteal force, or decreased iliopsoas force. *J Biomech* 2007;40:3725-31.
 116. Dilani Mendis M, Hides JA, Wilson SJ, et al. Effect of prolonged bed rest on the anterior hip muscles. *Gait Posture* 2009;30:533-7.
 117. Cowan SM, Crossley KM, Bennell KL. Altered hip and trunk muscle function in individuals with patellofemoral pain. *Br J Sports Med* 2009;43:584-8.
 118. Cowan SM, Blackburn MS, McMahon K, Bennell KL. Current Australian physiotherapy management of hip osteoarthritis. *Physiotherapy* 2010;96:289-95.
 119. Mendis MD, Wilson SJ, Stanton W, Hides JA. Validity of real-time ultrasound imaging to measure anterior hip

- muscle size: a comparison with magnetic resonance imaging. *J Orthop Sports Phys Ther* 2010;40:577-81.
120. Pua YH, Wrigley TV, Collins M, Cowan SM, Bennell KL. Association of physical performance with muscle strength and hip range of motion in hip osteoarthritis. *Arthritis Rheum* 2009;61:442-50.
121. Thorborg K, Petersen J, Magnusson SP, Holmich P. Clinical assessment of hip strength using a hand-held dynamometer is reliable. *Scand J Med Sci Sports* 2010;20:493-501.