

First use of the RANKL antibody denosumab in Osteogenesis Imperfecta Type VI

O. Semler^{1*}, C. Netzer^{2*}, H. Hoyer-Kuhn¹, J. Becker², P. Eysel³, E. Schoenau¹

¹Children's Hospital, University of Cologne, 50931 Cologne, Germany; ²Institute of Human Genetics, University of Cologne, 50931 Cologne, Germany; ³Department of Orthopaedic and Trauma surgery, University of Cologne, Cologne, Germany.

*These authors contributed equally

Abstract

Osteogenesis imperfecta (OI) is a genetically heterogeneous disease leading to bone fragility. OI-VI is an autosomal-recessive form caused by mutations in *SERPINF1*. There is experimental evidence suggesting that loss of functional *SERPINF1* leads to an activation of osteoclasts via the RANK/RANKL pathway. Patients with OI-VI show a poor response to bisphosphonates. We report on four children with OI-VI who had shown continuously elevated urinary bone resorption markers during previous treatment with bisphosphonates. We treated these children with the RANKL antibody denosumab to reduce bone resorption. **Intervention and results:** Denosumab (1 mg/kg body weight) was injected s.c. every 3 months. There were no severe side effects. Markers of bone resorption decreased to the normal range after each injection. N-terminal Propeptide of collagen 1 was measured in the serum during the first treatment cycle and decreased also. Urinary deoxypyridinoline/creatinine was monitored in a total of seven treatment cycles and indicated that bone resorption reached the pre-treatment level after 6-8 weeks. **Conclusion:** This was the first use of denosumab in children with OI-VI. Denosumab was well tolerated, and laboratory parameters provided evidence that the treatment reversibly reduced bone resorption. Therefore, denosumab may be a new therapeutic option for patients with OI-VI.

Keywords: Osteogenesis Imperfecta VI, *SERPINF 1*, RANKL Antibody, Denosumab, Pigment Epithelium-Derived Factor

Introduction

Osteogenesis imperfecta (OI) is a hereditary disease causing reduced bone mass, increased fracture rate, deformities of long bones, vertebral collapses and wormian bones. Non-skeletal findings such as blue sclera, hyperlaxity of ligaments and joints and dentinogenesis imperfecta can be associated to a variable degree. In the majority of patients OI is caused by dominant mutations in *COL1A1* or *COL1A2* that lead either to a quantitative or a qualitative defect in collagen type I¹. However, mutations affecting proteins involved in the modification or excretion of procollagen type I can give rise to recessive forms of OI². At present, patients with severe clinical symp-

toms are treated with intravenous bisphosphonates, in particular pamidronate and neridronate, regardless of the underlying gene defect^{3,4}.

OI-VI is a recessive form of OI that is characterized by an increased amount of non-mineralized osteoid in bone biopsies⁵. Additional clinical hallmarks are the only discrete symptoms at birth and the relatively late onset of fractures and deformities compared to other severe forms of OI. The skeletal symptoms show only a poor response to a bisphosphonate treatment⁶. OI-VI is caused by mutations in *SERPINF1* which encodes pigment epithelium-derived factor (PEDF), a protein with multiple functions^{7,8}. In patients with OI-VI and truncating *SERPINF1* mutations, PEDF is not detectable in peripheral blood, and this can

The authors have no conflict of interest.

Corresponding author: Dr. med. Oliver Semler, Children's Hospital, University of Cologne, Kerpenerstr. 62, D-50931 Cologne, Germany
E-mail: joerg.semmler@uk-koeln.de

Edited by: F. Rauch
Accepted 19 August 2012

Abbreviations:

OI = Osteogenesis imperfecta
PEDF = Pigment epithelium-derived factor
DPD = Deoxypyridinoline
P1CP = Procollagen-1 – C-Peptide
PTH = Parathyroid hormone
NTx = N-terminal telopeptide of type 1 collagen

Findings	Pat 1	Pat 2	Pat 3	Pat 4
OI type 2	VI	VI	VI	VI
Age at start of therapy [years]	9.4	6.9	18.5	5.7
<i>SERPINF1</i> mutation	c.324_325dupCT; p.Tyr109SerfsX5	c.1132C>T; p.Q378X	c.696C>G; p.Y232X	c.696C>G; p.Y232X
Duration of previous bisphosphonate treatment (years)	8.1	5.7	3.4	3.4
Color of sclera	white	white	white	white
Dentinogenesis imperfecta	no	no	no	no
Hypermobility of joints	no	no	no	no
Hearing impairment	no	no	no	no
Weight kg/BMI	19.7 / 16.6	14.7 / 14.1	51.4 / 35.7	10.8 / 13.6
Height (SD)	-4.0	-3.5	120 / - 9.9	89.0 / - 5.8
Mobility at last visit (BAMF) ¹⁶	6	6	2	4
Calcium [mmol/l]	2.26	2.24	2.35	2.29
Phosphorus [mmol/l]	1.48	1.52	1.16	1.37
Alkaline Phosphatase [U/l]	220	305	151	312
25-OH Vitamin D [μ g/l]	10.5	4.3	14.5	16.6
Bone density	0.641; -0.6	0.412; -2.6	1.014; -2.4 (With head)	0.373; -2.9
Whole body less head (g/cm ² ; z-score)				
Bone density L2-L4 (g/cm ² ; z-score)	0.515; -2.4	0.330; -4.3	0.691; -4.1	0.325; -4.3

Table 1. Clinical and laboratory findings at the start of the denosumab treatment.

be used as a diagnostic parameter⁹. Cell-culture experiments and an *in vivo* model provided evidence that PEDF inhibits osteoclast differentiation and hence bone resorption *via* osteoprotegerin (OPG) and RANKL. Receptor activator of NF- κ B (RANK), its ligand RANKL, and the decoy receptor OPG are central regulators of osteoclast development and function¹⁰. Denosumab is a blocking antibody to RANKL, thereby inhibiting osteoclast formation and bone degradation. Denosumab was first demonstrated to be effective in reducing osteoclastic activity and increasing bone mass in postmenopausal women and has been approved for the treatment of osteoporosis in 2010^{11,12}.

The new insights into the pathophysiology of OI-VI, gained by the identification of the underlying genetic defect, encouraged us to therapeutically target RANKL in patients with this severe OI subtype. We report the first experiences of a treatment with denosumab injections in four of our patients affected by OI-VI. These patients had displayed poor response to the standard bisphosphonate treatment. To our knowledge, this is the first report about children with OI treated with the RANKL antibody denosumab.

Case histories

Our four male patients presented with a severe OI phenotype and were tested negative for mutations in the genes *COL1A1* and *COL1A2*. Two of them were brothers, and they all had consanguineous parents from Turkey or from the United Arab Emirates. The clinical findings have been described in detail elsewhere⁷. In short, all patients had normal or near-normal ultrasound findings

during pregnancy (only one patient was reported to have a mild shortening of the femur). They were born spontaneously by vaginal delivery and presented healthy at birth. OI was diagnosed after the first fractures upon minimal traumata had occurred (around 6 months of age), followed by an increasing degree of bowing of the legs. Spine X-rays revealed multiple vertebral fractures and deformities. A bisphosphonate therapy with intravenous pamidronate was initiated following the protocol published by Rauch et al.¹. Later, the treatment regime was switched to intravenous neridronate, as the infusion protocol is more convenient for the patients¹³. In addition, the boys underwent surgical treatment of fractures and deformities with the insertion of intramedullary telescopic rods, and they received physiotherapy.

During bisphosphonate treatment vertebral size increased slightly and vertebral deformities decreased marginally. Additional fractures occurred in all patients, with a frequency from 0 to 7 fractures per year in both the lower and the upper extremities. Serum markers for calcium, vitamin D and parathyroid hormone (PTH) were measured during therapy. Urinary levels of deoxypyridinoline (DPD), a marker of osteoclast activity, were consistently elevated despite bisphosphonate treatment. Regardless of physiotherapy and rehabilitation, the mobility of the four patients remained very limited and was lower compared to other children with similar severity of OI, but with causal mutations in the genes *COL1A1* or *COL1A2*. Our patients were not able to bear weight on their legs and they were depending on a wheelchair.

Due to the consanguinity of the parents, we searched for homozygous mutations in the patients by whole-exome sequencing and discovered the disease causing mutations in *SERPINF1*⁷. A

	P1CP ($\mu\text{g/l}$)		Calcium [mmol/l] (2,20-2,65)		PTH [ng/l] (12-72)		NTx [nM/l] (12,9-79,8)		DPD/crea [nM/mM]	
	Pat 1	Pat 2	Pat 1	Pat 2	Pat 1	Pat 2	Pat 1	Pat 2	Pat 1	Pat 2
Day 1	265	231	2.34	2.24	15	13	42.8	41.5	70.8	33.3
Day 2		221	2.22	2.16	55	40	15.6	21.8	58.9	28.7
Day 7	157	230	2.34	2.10	23	56	6.7	8.1	23.2	25.1
Day 14	183	154	2.27	1.99	56	199	7.3	7.0	23.7	13.4
Day 29	95	161	2.26	2.21	57	61	7.1	11.8	25.2	22.7

Table 2. Laboratory parameters during the first denosumab treatment cycle of 2 patients. Changes of P1CP, calcium, PTH, NTx and DPD/crea levels during the first treatment cycle in the first two patients. P1CP, PTH and NTx were measured in the serum. DPD/crea was measured in spot urine probes. Calcium was measured in the serum and corrected for albumin levels. Patients were orally substituted with calcium and vitamin D starting 36 hours after the denosumab injections.

bone biopsy was performed in three of the patients and showed the typical histomorphometric findings of OI-VI with increased osteoid and an increased amount of osteoclasts (data not shown). The patients' clinical and laboratory findings at the start of denosumab treatment are summarized in Table 1.

Material and Methods

We obtained written informed consent from both parents of each patient to change the therapeutic regime. Denosumab was injected subcutaneously at a dose of 1 mg/kg body weight every three months, as described for adults treated with denosumab¹⁴.

During the first treatment cycle of the first two patients receiving denosumab, N-terminal telopeptide of type 1 collagen (NTx) as a serum marker of bone resorption was measured, and the serum level of pro-collagen-1-C-peptide (P1CP) was determined to assess changes in bone formation. NTx was measured in the serum with an enzyme immunoassay (Osteomark[®], Finland). Results were interpreted using reference data published by Orwoll et al¹⁵. Serum P1CP concentration was measured by a radio immune assay (Orion, Finland) and interpreted using the reference data provided by the manufacturer.

To monitor the individual course of inhibition of bone resorption, urinary deoxypyridinoline levels were measured in all four patients over the entire treatment period and normalized to urinary creatinine levels. The normalized DPD values were presented as DPD/crea [nM/mM]. DPD levels were determined from spot urine probes which the patients collected at home at least every second week. DPD was measured with the IMMULITE Pylinks-D 100 Kit (chemiluminescent immunoassay) (Siemens Healthcare Diagnostics, Germany). Age- and sex-matched reference data were obtained in our own laboratory by analyzing spot urine probes of 443 children. Urinary creatinine was quantified by the Jaffé method.

As additional parameters of bone metabolism we determined calcium and PTH levels in the serum. Calcium was measured with the Modular P-Modul[®] (Roche Diagnostics, Germany) and interpreted using a reference range of 2.20–2.65 mmol/l. PTH was measured with the Modular E-Modul[®]

(Roche Diagnostics, Germany) and interpreted with a reference range of 12-72 ng/l.

The mobility of the patients was assessed using the “Brief Assessment of Motor Function” (BAMF) scale. This scale classifies the motor function with 0 to 10 points, reflecting a patient's ability to roll, crawl or walk¹⁶.

Dual-energy x-ray absorptiometry (DXA) scans of the lumbar spine and total body were acquired with GE Lunar iDXA (GE Healthcare, Great Britain). The z-scores were provided by the appropriate software for pediatric patients (Encore Version 13.60.033).

With every blood-drawing, standard parameters controlling liver function (ALT, AST), renal function (creatinine), electrolyte metabolism (sodium, potassium, magnesium), inflammatory signs (CRP), cellular integrity (CK, LDH), hematopoiesis (Hb, MCV, MCHC, number of erythrocytes, lymphocytes and thrombocytes), and coagulation (PT, PTT) were determined in the patients by standard methods.

Results

The denosumab injections were well tolerated by all four patients, without any changes in blood pressure, heart rate or body temperature. Thirty-six hours after the injections, oral supplementation with calcium (750 mg per day) and vitamin D (500 international units per day) was started and was continued for two weeks. After three days of clinical monitoring, during which no adverse events were observed, the patients were discharged from hospital. Over the follow-up time of 5 to 33 weeks, the patients and their parents reported no side effects. One patient suffered a radiologically confirmed fracture of the right humerus after a mild trauma. Fracture healing was normal. Of note, the therapy was started sequentially in the four patients to ensure maximum safety. Therefore, the follow-up period and the number of treatment cycles differed between the patients.

The changes of calcium, P1CP, PTH, NTx and DPD/crea levels in the first two patients after first administration of denosumab are shown in Table 2. The serum calcium concentration decreased slightly and the PTH level increased within 48

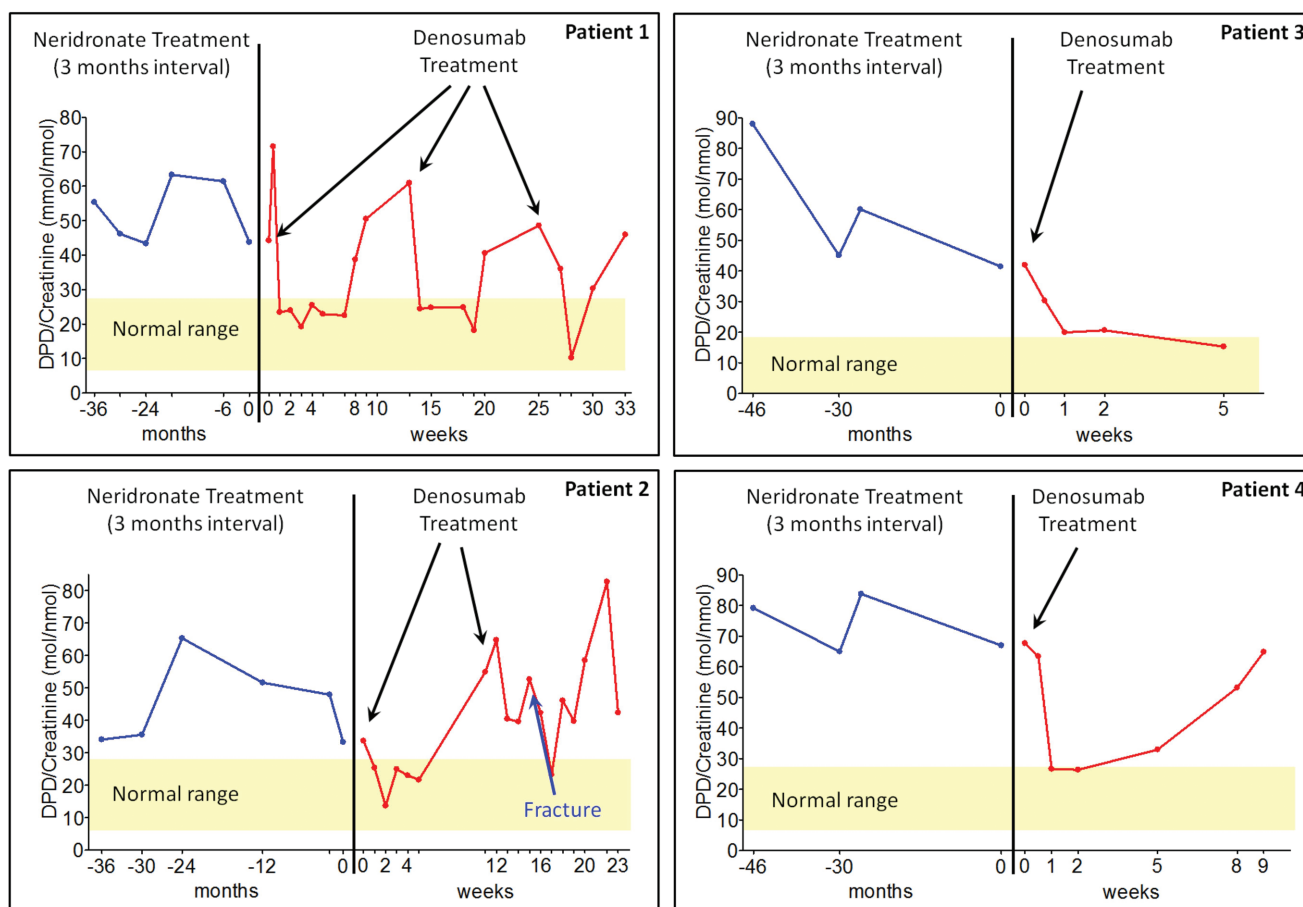


Figure 1. Urinary DPD/crea levels of four patients with OI-VI treated with denosumab. Each graph shows the levels during at least 36 months of bisphosphonate treatment with neridronate (blue line on the left side of the graphs) and the levels after the onset of denosumab injections. After 6 of the 7 injections, the DPD/crea levels decreased to the normal range within the next days (red line on the right side of the graphs for patients 1-4). Response to the second denosumab injection in patient 2 may have been disturbed by a fracture of the right humerus (blue arrow). DPD/crea levels slowly recovered during the follow-up period and reached the pre-treatment level after 6-8 weeks.

hours. None of the patients had symptoms of hypocalcaemia during the treatment period.

Intriguingly, NTx and DPD/crea as markers of bone resorption decreased into the reference range within a few days after the denosumab injections. A rapid drop of urinary DPD/crea levels into the reference range was observed in all four patients and after six of the seven denosumab injections administered so far (Figure 1). DPD/crea levels slowly recovered during the follow-up period and reached the pre-treatment level after 6-8 weeks, indicating that the suppression of bone resorption by denosumab is reversible.

All standard blood parameters repeatedly determined in the four patients showed no evidence for an impaired organ function as a hypothetical side-effect of the denosumab treatment (data not shown).

Discussion

Treatment with the RANKL antibody denosumab was well tolerated by all four patients with OI-VI. The injections caused

a degree of suppression of bone resorption, as measured by urinary DPD/crea levels, that had never been reached during at least three years of bisphosphonate treatment. The reduced bone resorption was also reflected by a decrease of NTx levels and an increase of PTH in the serum, as documented in the first two patients during their first denosumab treatment cycles. The marginal drop of serum calcium levels could be easily corrected by oral supplementation and can be considered as an indicator for the decreased ability of osteoclasts to resorb bone and to release calcium. Of note, we had not seen a clinically relevant decrease of calcium levels while these patients had been treated with bisphosphonates, and therefore the patients had not received oral supplementation routinely. Supplementation with calcium and vitamin D was only started when serum calcium level dropped and the PTH level increased after the denosumab injections and was stopped as soon as calcium and PTH levels normalized.

Parallel to the decrease of DPD/crea, we observed a decrease of PICP as a marker for osteoblastic activity. Such a PICP decrease has also been reported in osteoporotic adults

treated with denosumab and is also a typical effect of bisphosphonates¹⁷.

During the treatment period, one patient (patient 2) suffered a radiologically confirmed fracture of his right humerus after a mild trauma. The activation of bone remodeling during fracture healing may explain the rather poor effect on urinary DPD/crea levels observed in the second treatment cycle of this patient.

The interval between the denosumab injections was chosen based on experiences from adults with osteoporosis. However, our results indicate that a three-month interval might be too long for patients with OI-VI. An eight-week interval seems more appropriate to ensure a constant suppression of bone resorption by osteoclasts.

Bisphosphonates are known to be less effective in patients with OI-VI than in individuals with other types of OI⁶. The reasons for this have not been experimentally investigated, but they may be related to the fact that bisphosphonates bind to the mineralized bone surface and induce osteoclast apoptosis upon resorption. The increased amount of unmineralized osteoid in patients with OI-VI possibly impairs the ability of bisphosphonates to attach to the bone and hence reduces their toxicity for osteoclasts. Denosumab acts on osteoclasts through a different mechanism: Via inhibition of RANKL, it prevents the maturation and activation of osteoclasts before these cells adhere to the bone matrix. This therapeutic effect should be independent from the mineralization status of the bone, explaining our observation that denosumab more efficiently reduced bone resorption in patients with OI-VI than bisphosphonates.

In addition to its efficacy in normalizing bone resorption in patients with OI-VI, denosumab potentially offers another important advantage compared to the current standard therapy for OI: The humanized antibody degrades within 3-4 months after injection and hence does not remain in the body¹⁸. Bisphosphonates are stored in the skeleton for years, a fact that has led to an ongoing debate about their long-term safety for children^{19,20}. In the future, it may therefore be worth discussing whether denosumab could also be a treatment alternative for children with other subtypes of OI or with other osteoporotic diseases. In fact, a recent case report described the use of denosumab in a child with fibrous dysplasia and documented a good response with respect to bone pain, bone turnover markers, and regression of a femoral lesion²¹.

Our preliminary report is limited by the small number of patients with OI-VI and the differing follow-up periods, a consequence of the sequential treatment start which was necessary to ensure maximum safety for the patients. Further studies have to evaluate the effects of a long-term therapy with this new treatment approach on mobility, bone density and fracture rates, and will have to focus on potential long-term side effects. Nevertheless, this report is a striking example of the fact that a precise molecular diagnosis can have immediate implications for the therapeutic regimen. In the cases presented here, the time required to transfer the knowledge gained by the discovery of the underlying genetic defect from “bench to bedside” was less than a year, and the families potentially benefiting from the new insights into the disease pathology had partici-

pated in the research project leading to the identification of *SERPINF1* mutations in OI-VI⁷.

Acknowledgements

We would like to specially thank A. Stabrey for measuring deoxyypyridinoline and for preparing figure 1. We want to thank K. Boss for critically reading a draft version of the manuscript and K. Kloeckner-Muenter and M. Kron for administrative support. This study was supported by the “Eva Luise Köhler Forschungspreis für Seltene Erkrankungen” awarded to O.S., C.N., and E.S.

References

1. Rauch F, Glorieux FH. Osteogenesis imperfecta. *Lancet* 2004;363:1377-85.
2. Forlino A, Cabral WA, Barnes AM, Marini JC. New perspectives on osteogenesis imperfecta. *Nat Rev Endocrinol* 2011;7:540-57.
3. Glorieux FH, Bishop NJ, Plotkin H, Chabot G, Lanoue G, Travers R. Cyclic administration of pamidronate in children with severe osteogenesis imperfecta. *N Engl J Med* 1998;339:947-52.
4. Semler O, Beccard R, Palmisano D, et al. Reshaping of Vertebrae during Treatment with Neridronate or Pamidronate in Children with Osteogenesis Imperfecta. *Horm Res Paediatr* 2011;76:321-7.
5. Glorieux FH, Ward LM, Rauch F, et al. Osteogenesis imperfecta type VI: a form of brittle bone disease with a mineralization defect. *J Bone Miner Res* 2002;17:30-8.
6. Land C, Rauch F, Travers R, Glorieux FH. Osteogenesis imperfecta type VI in childhood and adolescence: effects of cyclical intravenous pamidronate treatment. *Bone* 2007;40:638-44.
7. Becker J, Semler O, Gilissen C, et al. Exome Sequencing Identifies Truncating Mutations in Human *SERPINF1* in Autosomal-Recessive Osteogenesis Imperfecta. *Am J Hum Genet* 2011;88:362-71.
8. Homan EP, Rauch F, Grafe I, et al. Mutations in *SERPINF1* cause osteogenesis imperfecta type VI. *J Bone Miner Res* 2011;26:2798-803.
9. Rauch F, Husseini A, Roughley P, Glorieux FH, Moffatt P. Lack of circulating pigment epithelium-derived factor is a marker of osteogenesis imperfecta type VI. *J Clin Endocrinol Metab* 2012;97:E1550-6.
10. Akiyama T, Dass CR, Shinoda Y, et al. PEDF regulates osteoclasts via osteoprotegerin and RANKL. *Biochem Biophys Res Commun* 2009;391:789-94.
11. Cummings SR, San Martin J, McClung MR, et al. Denosumab for prevention of fractures in postmenopausal women with osteoporosis. *N Engl J Med* 2009;361:756-65.
12. Iqbal J, Sun L, Zaidi M. Denosumab for the treatment of osteoporosis. *Curr Osteoporos Rep* 2010;8:163-7.
13. Gatti D, Antoniazzi F, Prizzi R, et al. Intravenous neridronate in children with osteogenesis imperfecta: a randomized controlled study. *J Bone Miner Res* 2005; 20:758-63.

14. McClung MR, Lewiecki EM, Cohen SB, et al. Denosumab in postmenopausal women with low bone mineral density. *N Engl J Med* 2006;354:821-31.
15. Orwoll ES, Bell NH, Nanes MS, et al. Collagen N-telopeptide excretion in men: the effects of age and intrasubject variability. *J Clin Endocrinol Metab* 1998;83:3930-5.
16. Cintas HL, Siegel KL, Furst GP, Gerber LH. Brief assessment of motor function: reliability and concurrent validity of the Gross Motor Scale. *Am J Phys Med Rehabil* 2003;82:33-41.
17. Kendler DL, Roux C, Benhamou CL, et al. Effects of denosumab on bone mineral density and bone turnover in postmenopausal women transitioning from alendronate therapy. *J Bone Miner Res* 2010;25:72-81.
18. Sutjandra L, Rodriguez RD, Doshi S, et al. Population pharmacokinetic meta-analysis of denosumab in healthy subjects and postmenopausal women with osteopenia or osteoporosis. *Clin Pharmacokinet* 2011;50:793-807.
19. Yoon RS, Hwang JS, Beebe KS. Long-term bisphosphonate usage and subtrochanteric insufficiency fractures: a cause for concern? *J Bone Joint Surg Br* 2011;93:1289-95.
20. Thompson RN, Phillips JR, McCauley SH, Elliott JR, Moran CG. Atypical femoral fractures and bisphosphonate treatment: experience in two large United Kingdom teaching hospitals. *J Bone Joint Surg Br* 2012;94:385-90.
21. Boyce A, Chong W, Yao J, et al. Denosumab treatment for fibrous dysplasia. *J Bone Miner Res* 2012;27:1462-70.