

Clinical Quiz

Tertiary hyperparathyroidism in a patient with X-linked Hypophosphatemic Rickets

S. Tournis¹, T. Georgoulas², C. Zafeiris², C. Papalexis³, K. Petraki³, G.P. Lyritis²

¹Laboratory for Research of Musculoskeletal System "Theodoros Garofalidis", KAT Hospital, University of Athens, Athens, Greece; ²Post-graduate Course on Metabolic Bone Disease, University of Athens, Greece; ³Pathology Department, Metropolitan Hospital, Piraeus, Greece

Keywords: X-linked Hypophosphatemic Rickets (XLHR), FGF23, Hyperparathyroidism

Case

A 29-year-old female (Weight=50 kg, Height=152 cm, Body Mass Index= 21.6 Kg/m², target height: 151.5 cm) with symptomatic XLHR (X-linked Hypophosphatemic Rickets) since childhood was referred for evaluation of hypercalcemia. At the age of three years, during evaluation for growth retardation and features of rickets along with hypophosphatemia, she received the diagnosis of XLHR. Family history was negative for XLHR. Treatment consisted of oral phosphate salts and alfacalcidol, therapy that was continued until the age of 18 yrs. After the age of eighteen years she received intermittently alfacalcidol without phosphate salts. The following ten years before current evaluation she developed nephrocalcinosis diagnosed by ultrasound and renal computed tomography (Figure 1a,b). By that time she reported progressive increase in serum calcium levels.

At presentation, while off alfacalcidol treatment for at least 3 months, she reported weakness and generalized muscle pain, symptoms suggestive of osteomalacia. There was no history of fractures, while no deformities were detected. Laboratory examinations were compatible with tertiary hyperparathyroidism (Table 1). Bone mineral density (BMD) measurements by Dual X-ray Absorptiometry (DXA) at the lumbar spine and hip were within normal range. The patient underwent genetic testing for PHEX mutations which revealed a new mutation/variation at the 6th nucleotide downstream of the coding exon 14: c.1586+6T>A. Prediction programs predicted that this varia-

Abbreviations

XLHR: X-linked Hypophosphatemic Rickets
BMD: Bone mineral density
b.i.d.: <i>bis in die</i> (twice a day)
FGF-23: fibroblast growth factor-23
DXA: Dual X-ray Absorptiometry
PHEX gene: phosphate-regulating gene with homologies to endopeptidases on the X chromosome
PTH: parathyroid hormone
q.d.: <i>quaque die</i> (every day)
q.i.d.: <i>quid quarter in die</i> (four times a day)
t.i.d.: <i>ter in die</i> (three times a day)

tion will have an effect on correct RNA splicing (Jongbloed J.D.H., PhD, Department of Genetics, UMCG, Groningen, the Netherlands).

Neck ultrasound showed enlargement of the two inferior parathyroid glands (right 21*9 mm and left 10*6 mm), while parathyroid imaging with ^{99m}Tc- sestamibi scintigraphy revealed a hyperfunctioning right inferior parathyroid gland.

In order to improve the vitamin D and phosphate deficit prior to surgical intervention, the patient was treated with cinacalcet 30 mg b.i.d. (twice a day) for 2 weeks, followed by addition of alfacalcidol 0.5 µg q.d. (once a day) and phosphate 500 mg q.i.d. (four times a day) with excellent results. There was normalization in serum calcium levels, increase in phosphate levels, while parathyroid hormone (PTH) levels decreased significantly, to almost normal levels. Two months later the patient underwent bilateral cervical exploration. All four parathyroid glands were identified and subtotal parathyroidectomy was performed. Histological examination revealed diffuse chief-cell hyperplasia with compact, trabecular and/ or follicular growth pattern (Figure 1c,d).

In the immediate post-operative period the patient was treated with oral calcium [500 mg t.i.d. (three times a day)] and alfacalcidol (1.5 µg q.d). Progressively calcium admin-

The authors have no conflict of interest.

Corresponding author: Symeon Tournis M.D., PhD, Laboratory for Research of Musculoskeletal System, "Theodoros Garofalidis", KAT Hospital, University of Athens, 10th Athinas str., Kifisia, PC 14561, Athens, Greece
E-mail: stournis@med.uoa.gr

Edited by: P. Makras
Accepted 15 July 2011

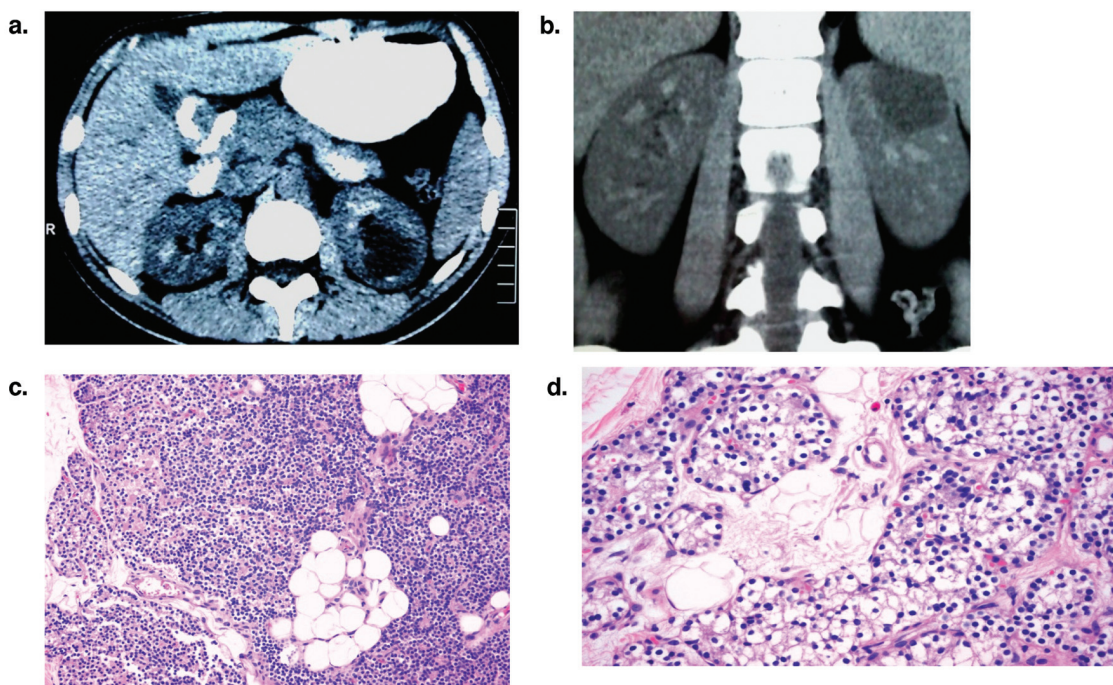


Figure 1. a and b: Axial (a) and coronal (b) abdominal CT images compatible with nephrocalcinosis. **c:** Hyperplastic parathyroid gland composed predominately by chief cells and a small component of oxyphilic cells (H-E x 100). **d:** Area of another hyperplastic parathyroid gland composed predominately by clear cells (H-E x 200).

	2 yrs prior ¹	Baseline ²	2 months ³	8 months ⁴	14 months ⁴
Ca (mg/dl) (8.2-10.2)	10.48	10.50	9.5	9.0	9.3
P (mg/dl) (2.7-4.5)	1.90	1.4	2.1	2.2	2.2
Creatinine (mg/dl) (0.5-1.1)	0.6	0.6		0.59	0.62
Albumin (gr/L) (3-5)		4.0		4.4	4.2
iPTH (pg/ml) (10-65)		106.0	70.0	42.0	48.0
25 (OH)D (ng/ml) (20-58)		15.6			
1,25 (OH)2D (pg/ml) (16-42)		29.0			
Ca U24h (mg) (100-250)		111.0		88.0	110.0
P U24h (mg) (400-1300)		400.0		621.0	732.0
Creatinine U 24h (mg)		900.0		963.0	989.0
TMP/GFR (mg/dl) (2.5-4.2)		1.23		1.85	1.75
V U (L)		1.10		1.70	1.80
BMD L1-L4 (mg/cm ² / z-score)		1.455/2.7			1.521/2.8
BMD FN (mg/cm ² / z-score)		0.957/0.0			0.985/0.0
BMD trochanter (mg/cm ² / z-score)		1.004/2.2			0.971/1.6
BMD Total Hip (mg/cm ² / z-score)		1.109/1.2			1.190/1.3

1. Treatment consisted of intermittent alphacalcidol therapy (1 μ g q.d.). 2. No treatment for 3 months. 3. Treatment consisted of Cinacalcet 30 mg bid, alphacalcidol 0.5 μ g q.d., phosphate 500 mg q.i.d., 4. Alphacalcidol 1 μ g q.d. Surgery was performed about 3 months after the initial evaluation (baseline). TMP/GFR: Maximum tubular resorption of phosphorus factored for glomerular filtration rate. DXA measurements were performed using Lunar Prodigy Pro machine.

Table 1. Baseline and follow-up biochemical and DXA parameters.

istration was discontinued and alphacalcidol treatment was tapered to 1 µg q.d. At both 6 and 12 months postoperatively calcium and PTH levels remained within normal range, while phosphate levels remained low, albeit higher compared to preoperative levels. Maximum tubular resorption of phosphorus factored for glomerular filtration rate (TMP/GFR) showed substantial improvement following successful parathyroidectomy. DXA measurements at the LS and hip did not show any particular change.

Commentary

X-linked hypophosphatemic rickets (XLHR) represents the most common heritable hypophosphatemic disorder¹. XLHR is caused by inactivating mutations of the PHEX gene (phosphate-regulating gene with homologies to endopeptidases on the X chromosome), that encodes a transmembrane endopeptidase predominantly expressed in mature osteoblasts and osteocytes.

The biochemical hallmark of XLHR is hypophosphatemia due to impaired renal tubular phosphate reabsorption and inappropriately normal or low calcitriol levels. Increased fibroblast growth factor-23 (FGF-23) levels seem to have a central role in the pathogenesis of XLHR, leading to inhibition of the sodium-phosphate symporter 2a and 2c (NPT2a and 2c) at the proximal tubule and reduced expression of renal 1 α -hydroxylase. However the connection between PHEX inactivating mutations and increased FGF-23 levels is still unresolved². XLHR, if left untreated, leads to growth retardation and impaired skeletal mineralization (rickets/osteomalacia).

Current treatment of XLHR consists of administration of vitamin D analogs and phosphate salts. However even with optimal treatment, *long-term* phosphate and calcitriol treatment may lead to nephrocalcinosis and secondary or tertiary hyperparathyroidism (THP) associated with aggravation of hypophosphatemia, severe *bone disease* and *renal* impairment.

Secondary hyperparathyroidism is a known complication of XLHR. The pathogenesis is multifactorial including phosphate-mediated postprandial reduction in calcium levels, phosphate and FGF23 mediated reduction in calcitriol production at the renal tubule and possible direct stimulating action of phosphate at the parathyroid cell. On the contrary FGF23 seems to directly decrease PTH secretion and increase 1- α hydroxylase activity at the parathyroid cells. More than three hundred XLHR patients, complicated with secondary or tertiary hyperparathyroidism, have been reported with ages ranging from 16 to 53 years old, but the exact frequency of THP in XLHR patients is still unclear³. However, there seems to be a higher incidence of the development of THP in XLHR patients treated with vitamin D plus high dose versus low dose oral phosphate salts³.

Apart from the aforementioned secondary changes, several reports point to altered PTH secretory dynamics in untreated patients with XLHR. Carpenter et al⁴ demonstrated alterations in the circadian rhythm of PTH secretion, with an exaggerated nocturnal rise of both mid-molecule and intact PTH in parallel with an increase in serum phosphate concentrations, even in untreated patients. This finding might be related to the abun-

dant expression of PHEX, membrane endopeptidase, at the parathyroid cell. Thus it is possible that hyperparathyroidism in patients with XLHR may be also related to loss of PHEX function in the parathyroid gland by either interfering with normal PTH mRNA cleavage or with the PTH degradation within or outside the parathyroid gland.

Nephrocalcinosis is another frequent complication in XLHR. It is generally observed in XLHR patients treated with high dose oral phosphate and vitamin D preparations. Indeed large doses of calcitriol increase the risk of hypercalcemia and hypercalciuria, while patients with XLHR and nephrocalcinosis had higher urinary excretion of phosphate than untreated patients or those without nephrocalcinosis and they received higher phosphate doses⁵.

The only effective treatment of THP in XLHR is parathyroidectomy. The gold standard is neck exploration with identification and excision of abnormal parathyroid tissue. Pathologic examination most often demonstrates multiple-gland hyperplasia. Given the high risk of hungry bone syndrome in XLHR patients it is prudent to restore the vitamin deficit prior to surgery. The use of cinacalcet, a type-2 calcium sensing receptor agonist, approved for the treatment of hyperparathyroidism in stage 5 CKD, parathyroid cancer and in cases of primary hyperparathyroidism unable to undergo surgery, gives the opportunity to improve the vitamin D status of the patient without aggravating hypercalcemia. Finally there are reports of cinacalcet use in XLHR patients and patients with tumor-induced osteomalacia with normal PTH and calcium levels, leading to improvement in phosphate levels due to reduction in PTH-mediated phosphaturia.

In conclusion, it is important to minimize the risk of hyperparathyroidism in XLHR patients. Oral phosphate combined with vitamin D analogues remains the standard treatment. It is challenging to find a balance in which phosphate and calcitriol adequately treat the rickets without causing parathyroid hyperfunction, hypercalcemia and hypercalciuria. Calcimimetic compounds which decrease PTH secretion may prove useful for the treatment of hyperparathyroidism. Tertiary hyperparathyroidism is effectively treated with parathyroidectomy but is associated with profound hungry bone syndrome and necessitate careful management. Future treatment of XLHR may include the direct targeting of FGF23 protein or FGF23 receptor. More studies are needed to elucidate the prevalence and natural history of abnormal PTH regulation in XLHR, the role of mutant PHEX gene in inducing parathyroid hormone secretion and the optimal interventions.

References

1. DiMeglio LA, White KE, Econs MJ. Disorders of phosphate metabolism. *Endocrinol Metab Clin North Am* 2000;29:591-609.
2. Quarles DL. Endocrine functions of bone in mineral metabolism regulation. *J Clin Inv* 2008;118:3820-8.
3. Knudtzon GJ, Halse J, Monn E, Nesland A, Nordal KP,

- Paus P, Seip M, Sund S, Sodal G. Autonomous hyperparathyroidism in X-linked hypophosphatemia. *Clin Endocrinol (Oxf)* 1995;42:199-203.
4. Carpenter TO, Mitnick MA, Ellison A, Smith C, Insogna KL. Nocturnal hyperparathyroidism: a frequent feature of X-linked hypophosphatemia. *J Clin Endocrinol Metab* 1994;78:1378-83.
5. Taylor A, Sherlman NH, Norman ME. Nephrocalcinosis in X-linked hypophosphatemia: effect of treatment versus disease. *Pediatr Nephrol* 1995;9:173-175.
-

Questions

1. In patients with XLHR conservative treatment consists:

- A. Phosphate salts
- B. Phosphate salts and cholecalciferol
- C. Phosphate salts and vitamin D analogues

Critique

Treatment with phosphate salts only, does not correct the vitamin D deficit and may exaggerate hyperparathyroidism, while treatment with cholecalciferol will not correct the vitamin D deficit, given that the elevated FGF23 blocks the conversion of 25(OH) D to calcitriol.

The correct answer is C.

2. The pathogenesis of hyperparathyroidism in XLHR patients includes:

- A. Postprandial increase in phosphate levels
- B. Intrinsic abnormalities in PTH secretory dynamics
- C. Direct increase of PTH by FGF23
- D. A and B

Critique

In vitro studies demonstrate that FGF23 decreases PTH production by the parathyroids. Both postprandial increase in phosphate levels and intrinsic abnormalities in PTH secretory dynamics have been implicated in the development of hyperparathyroidism in XLHR.

The correct answer is D.

3. Patients with XLHR and tertiary hyperparathyroidism should be managed with:

- A. Parathyroidectomy
- B. Long term treatment with cinacalcet
- C. Bisphosphonate

Critique

Cinacalcet may be used for a short period in order to improve vitamin D status without causing hypercalcemia. However given that cinacalcet might increase urinary calcium excretion, more studies are needed in order to implement long term cinacalcet treatment. Finally bisphosphonates have been used in patients with primary hyperparathyroidism with low BMD with good results. However in XLHR the underlying bone disease is rickets/osteomalacia that might be aggravated by bisphosphonates. Furthermore BMD in XLHR is generally preserved.

The correct answer is A.