

Clinical Quiz

# Coincidence of severe primary hyperparathyroidism and primary hypothyroidism in a postmenopausal woman with low bone mass – initial conservative management

A.D. Anastasilakis<sup>1</sup>, S.A. Polyzos<sup>2</sup>, E. Karathanasi<sup>3</sup>, Z. Efstathiadou<sup>3</sup>

<sup>1</sup>Department of Endocrinology, 424 General Military Hospital, Thessaloniki, Greece;

<sup>2</sup>Second Medical Clinic, Medical School, Aristotle University of Thessaloniki, Ippokration Hospital, Thessaloniki, Greece;

<sup>3</sup>Department of Endocrinology, Hippokration General Hospital, Thessaloniki, Greece

**Keywords:** Primary Hyperparathyroidism, Hypothyroidism, Metabolic Bone Disease, Osteoporosis, Zoledronate

## Case

A 70 year-old Caucasian female (weight 71 kg, BMI 31.6 kg/m<sup>2</sup>) was referred to the outpatient clinics of the Department of Endocrinology, 424 Military Hospital, Thessaloniki, Greece because of newly diagnosed hip osteopenia.

The patient reported weakness, back pain and arthralgias without recent fractures and a positive family history of osteoporosis. Despite her kyphosis, lumbar spine bone mineral density (BMD) was normal (T-score -0.97) while non-dominant femoral neck BMD was low (T-score -2.12). Plain radiographs of the spine showed kyphosis and a moderate wedge fracture at T7 (Figure 1A). The baseline hematology and biochemistry testing revealed normochrome-normocytic anemia (Ht: 33%), severe hypercalcaemia and hypophosphataemia with markedly increased total alkaline phosphatase and slightly impaired renal function (Table 1). Subsequent hormone testing revealed markedly increased parathyroid hormone (PTH), normal 25-hydroxyvitamin D and, surprisingly, severe primary hypothyroidism [TSH: 54.6 µIU/ml, normal range (NR) 0.4-4; FT4 0.37, NR 0.84-1.76]. Although probably unnecessary due to the clear-cut picture of PTH-induced hypercalcemia, testing for other causes of hypercalcaemia, including protein electrophoresis, bone scintigraphy and mammography, was conducted, in order to rule out coincidence of primary hyperparathyroidism (pHPT) with other diseases, and turned out to be negative.

Parathyroid imaging with <sup>99m</sup>-technetium sestamibi scintigraphy revealed a hyperfunctioning right inferior parathyroid gland (Figure 1B) and neck ultrasound showed a 2.4 x 1.5 cm nodule under the lower pole of the right lobe of the thyroid gland in proximity with the right common carotid artery and the right jugular vein (Figure 1C). Fine-needle biopsy (FNB) of the nodule was performed and PTH was measured in the needle wash obtained during aspiration, returning a value of 7720 pg/ml – more than 3 times higher the patient's plasma value.

The patient was managed with adequate hydration with normal saline for her hypercalcaemia and substitution therapy with L-thyroxine 100 µg daily for her hypothyroidism. In order to further lower her serum calcium (Ca) and simultaneously improve her bone mass, an intravenous infusion of zoledronate 5 mg was administered. Serum Ca was reduced two days later; however, serum phosphate (P) was further reduced (Table 1). Therefore, phosphate 500 mg t.i.d. orally was administered for 20 days. Then, in sight of the risks of deteriorating her renal function and causing extraosseous calcifications through precipitation of calcium phosphate, phosphate was discontinued. Subsequently, serum Ca levels increased again, due to both an escape from the zoledronate's effect and the phosphate's cessation. Therefore, the patient was prescribed cinacalcet 30 mg b.i.d. and subsequently t.i.d. orally which lowered her calcium levels (Table 1). She is currently waiting to be subjected to parathyroidectomy.

## Commentary

Secondary osteoporosis should always be in mind in any case of low bone mass. During the evaluation of an osteoporotic patient PTH and thyroid hormones should be considered<sup>1</sup>. Both PTH and thyroid hormone excess affect preferably the cortical bone while the cancellous bone is relatively preserved; consequently, the decrease in BMD is more evident in

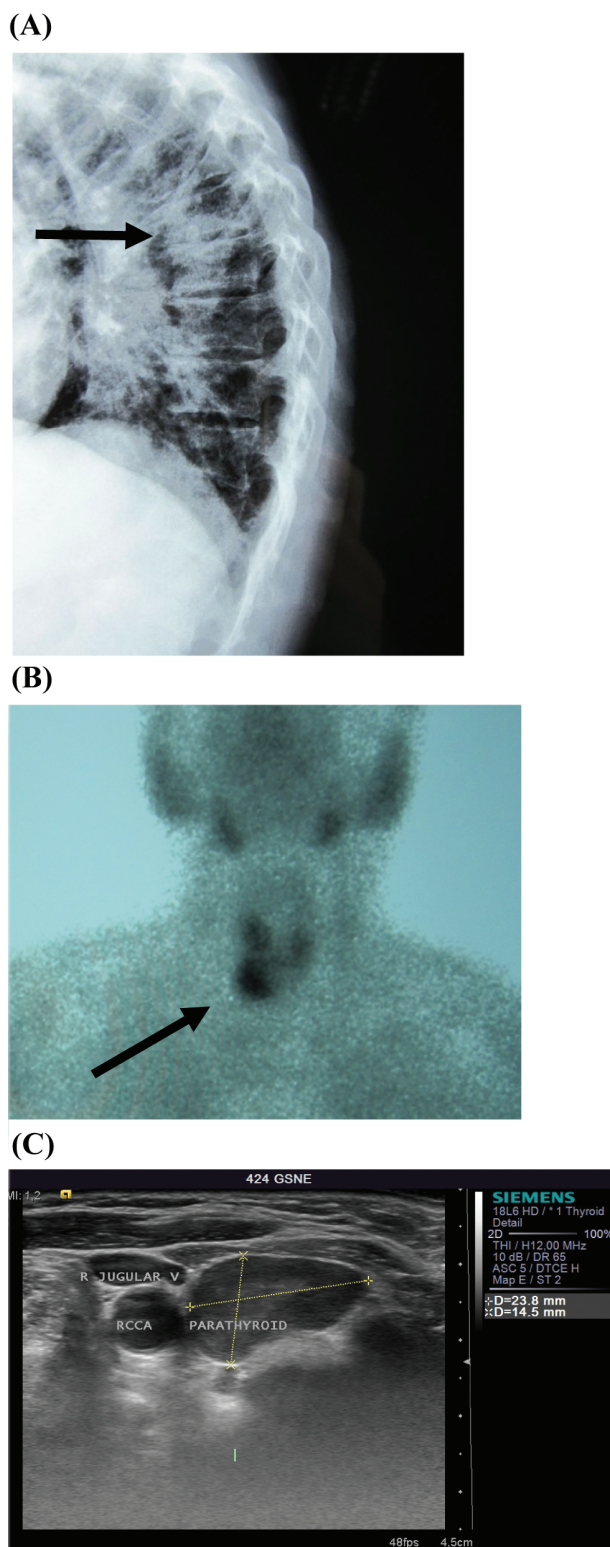
The authors have no conflict of interest.

Corresponding author: Dr. Athanasios Anastasilakis, Soulini 4, 566 25 Sykies, Greece

E-mail: anastath@endo.gr

Edited by: P. Makras

Accepted 29 December 2010



**Figure 1.** (A) Profile plain radiograph of the thoracic spine showing a wedge vertebral fracture at T7 (arrow). (B) Parathyroid scintigraphy with  $^{99m}\text{Tc}$ -sestamibi depicting a hyperfunctioning right inferior parathyroid gland (arrow). (C) neck ultrasound revealing an enlarged parathyroid gland below the lower pole of the right lobe of the thyroid gland in proximity with the right common carotid (RCCA) and the right jugular vein (R JUGULAR V).

predominantly cortical sites (forearm and hip) as compared with predominantly trabecular sites (spine)<sup>2</sup>. Therefore, in case of increased PTH or thyroid hormone levels BMD should be measured at both the lumbar spine and the hip. Conversely, when a patient presents with a normal lumbar spine but a low hip BMD measurement, as in our case, the likelihood of pHPT or hyperthyroidism should be considered.

Our patient had concurrently severe pHPT and hypothyroidism. The latter is characterized by the opposite effects than hyperthyroidism, namely an increase in BMD, more evident in cortical sites<sup>3</sup>. Thus, there were contradictory effects of pHPT and hypothyroidism in her bone mass; however, it seems that in our patient the effect of pHPT predominated, resulting in low hip BMD.

Given the relative preservation of cancellous bone in pHPT, it would be anticipated that fractures would be more common at cortical sites. Nevertheless, most studies have demonstrated a considerably higher risk of vertebral instead of hip fractures<sup>2</sup>, in accordance with the fracture in T7 evident in our patient's X-rays. On the other hand, in hypothyroidism fracture risk may paradoxically be increased, probably due to the presence of other diseases affecting the bone fragility. The finding of the thoracic fracture in our patient highlights the value of radiographic evaluation of the spine despite normal spine BMD, especially in a patient with low hip BMD.

The treatment of choice for bone disease in pHPT is surgical removal of the hyperfunctioning parathyroid tissue<sup>2</sup>. In patients with pHPT before the surgery or in patients unwilling or unable to be subjected to surgery or with persistent or recurrent pHPT, other treatment modalities, including antiresorptives and calcimimetics (cinacalcet), could be used. Both oral (alendronate, risedronate) and intravenous (pamidronate) bisphosphonates have been administered in pHPT<sup>4</sup>. All of them decreased bone turnover and increased BMD at both the lumbar spine and proximal femur. However, their effect on serum Ca has been inconsistent; it is possible that bisphosphonates slightly lower serum Ca while further raise PTH levels<sup>5</sup>. Hormone replacement therapy (HRT) has also increased BMD at all sites and lowered total Ca but did not affect ionized Ca or PTH levels<sup>4</sup>. Raloxifene also lowered bone turnover and preserved BMD in pHPT patients while slightly decreased total Ca without affecting PTH levels. Denosumab is expected to have a similar to bisphosphonates effect on bone turnover and BMD; however, to our knowledge, it has not been tested in pHPT patients yet. Cinacalcet is a calcimimetic agent that interacts with the calcium sensing receptor (CaSR) in the parathyroid cells thereby inhibiting PTH secretion. It reduces both serum Ca and PTH levels and increases serum P in a dose-dependent manner; however, it does not reduce bone turnover or improve BMD<sup>4</sup>.

In our patient a variety of the above treatments was used in an attempt to temporarily control hypercalcaemia and/or preserve bone mass, in sight of the forthcoming parathyroidectomy, including zoledronate, phosphate salts and cinacalcet. On the other hand, treatment of the hypothyroidism with thyroxine is associated with a short-term decrease in BMD. We

	Ca (mg/dl)	P (mg/dl)	ALP (IU/l)	PTH (pg/ml)	25(OH)D <sub>3</sub> (ng/ml)	Cr (mg/dl)
<i>Normal range</i>	<i>8.4-10.2</i>	<i>2.7-4.5</i>	<i>45-140</i>	<i>7-53</i>	<i>9.0-37.6</i>	<i>0.6-1.1</i>
Baseline	14.1	2.1	560	2163	19.5	1.3
2 days after zoledronate	11.6	1.0	488			1.3
Under phosphate 1500 mg/d	9.0	2.3	379			1.4
10 days after phosphate discontinuation	13.5	2.0	360			1.3
Under cinacalcet 60 mg/d	11.9	3.0	447			1.3
Under cinacalcet 90 mg/d	11.8	2.3	549			1.4

*Ca: serum calcium, P: serum phosphate, ALP: total alkaline phosphatase, PTH: intact parathyroid hormone, 25(OH)D<sub>3</sub>: 25-hydroxy-vitamin D<sub>3</sub>, Cr: creatinine.*

**Table 1.** Changes in the biochemical parameters of our patient with different treatment options.

used cinacalcet only after phosphate salts' discontinuation led in a recurrence of hypercalcaemia. It would probably be more efficient to co-administer the two agents; however, due to the reduced serum Ca value after the zoledronate infusion and the significantly higher cost of cinacalcet, we chose to keep it as a reserve in case of phosphate failure.

Our patient had mildly impaired renal function. This may have resulted from both the longstanding, severe hyperparathyroidism and the severe hypothyroidism. In pHPT the development of renal insufficiency is related to the degree and duration of hypercalcaemia while in severe hypothyroidism the increase in serum creatinine is usual but reversible after the restoration of euthyroidism. Therefore, in our case, persistently increased creatinine levels could be attributed to pHPT. Our choice to infuse zoledronate was of some risk, since in patients with osteoporosis and normal renal function zoledronate infusion has been associated with transient increases in serum creatinine. Furthermore, subsequent oral phosphate administration could cause precipitation of calcium phosphate salts in the kidneys and further deteriorate renal function. On the other hand, cinacalcet can be safely used in renal impairment, as it is mainly metabolized in the liver, with less than 1% of the parent drug excreted in the urine; however, its long-term effect on renal function is currently unknown. Therefore, parathyroidectomy remains the safest choice in patients with pHPT and renal impairment.

In conclusion, in any case of osteoporosis secondary causes should always be ruled out. In the case of pHPT low bone

mass, especially in cortical bone sites, is expected. Parathyroidectomy is the treatment of choice in patients with hyperparathyroid bone disease and/or impaired renal function. Alternative modalities that could lower serum Ca and preserve or increase BMD include antiresorptives, mainly bisphosphonates, and/or calcimimetics.

## References

1. Tannenbaum C, Clark J, Schwartzman K, et al. Yield of laboratory testing to identify secondary contributors to osteoporosis in otherwise healthy women. *J Clin Endocrinol Metab* 2002;87:4431-7.
2. Bilezikian JP, Khan AA, Potts JT Jr. Guidelines for the management of asymptomatic primary hyperparathyroidism: summary statement from the third international workshop. *J Clin Endocrinol Metab* 2009;94:335-9.
3. Coindre JM, David JP, Riviere L, et al. Bone loss in hypothyroidism with hormone replacement. A histomorphometric study. *Arch Intern Med* 1986;146:48-53.
4. Makras P, Papapoulos SE. Medical treatment of hypercalcaemia. *Hormones (Athens)*. 2009;8:83-95.
5. Polyzos SA, Anastasilakis AD, Terpos E. Transient secondary hyperparathyroidism following intravenous infusion of zoledronic acid. *Support Care Cancer* 2009; 17:1329-30.

## Questions

1. In primary hyperparathyroidism (pHPT) bone loss is:
- A. Equally distributed in both cancellous and cortical sites
  - B. Mainly detected in cancellous bone sites with relative preservation of cortical bone
  - C. Mainly detected in cortical bone sites with relative preservation of cancellous bone

### *Critique*

Patients with pHPT may have decreased bone mineral density (BMD), particularly at predominantly cortical sites (forearm and hip) as compared with predominantly cancellous sites (spine). The correct answer is C.

2. The best choice for conservative treatment of low bone mass due to pHPT is:
- A. Teriparatide
  - B. A bisphosphonate
  - C. Denosumab
  - D. Cinacalcet

*Critique*

In patients with pHPT, bisphosphonates are effective in decreasing bone turnover and improving BMD; furthermore, they may slightly decrease serum calcium. Denosumab has not been tested in pHPT while teriparatide is clearly contraindicated. Cinacalcet reduces both serum calcium and PTH levels; however, it does not reduce bone turnover or improve BMD. The correct answer is B.

3. In a patient with severe hypercalcaemia and bone disease due to pHPT and mild to moderate renal insufficiency the treatment option with the smallest risk of further deteriorating renal function is:

- A. Zoledronate
- B. Cinacalcet
- C. Parathyroidectomy

*Critique*

Zoledronate has a potential nephrotoxicity even in patients with normal renal function. Cinacalcet exerts no unfavourable effect on renal function, given that it is mainly metabolized in the liver; however, its long-term renal safety is currently unknown and probably has no effect on hyperparathyroid bone disease. Therefore, to date parathyroidectomy remains the preferable option for handling renal impairment in pHPT. The correct answer is C.