

Biology of implant osseointegration

A.F. Mavrogenis¹, R. Dimitriou¹, J. Parvizi², G.C. Babis¹

¹First Department of Orthopaedics, Athens University Medical School, Athens, Greece;

²Rothman Institute of Orthopaedics, Jefferson University, Pennsylvania, USA

Abstract

Osseointegration refers to a direct structural and functional connection between ordered, living bone and the surface of a load-carrying implant. Currently, an implant is considered as osseointegrated when there is no progressive relative movement between the implant and the bone with which it has direct contact. A direct bone contact as observed histologically may be indicative of the lack of a local or systemic biological response to that surface. It is therefore proposed that osseointegration is not the result of an advantageous biological tissue response but rather the lack of a negative tissue response. The rationale of the present review is to evaluate the basic science work performed on the concept of biology of osseointegration, and to discuss the specific factors as they may relate to osseous healing around an implant.

Keywords: Osseointegration, Biology

Introduction

Osseointegration or osteointegration refers to a direct bone-to-metal interface without interposition of non-bone tissue. This concept has been described by Branemark, as consisting of a highly differentiated tissue making "a direct structural and functional connection between ordered, living bone and the surface of a load-carrying implant"^{1,2}. Through his initial observations on osseointegration, Branemark showed that titanium implants could become permanently incorporated within bone that is, the living bone could become so fused with the titanium oxide layer of the implant that the two could not be separated without fracture. It occurred to this investigator that such integration of titanium screws and bone might be useful for supporting dental prostheses on a long-term basis¹.

From this discovery in experiments focused on observing the micromovements of bone, through its laboratory development and initial application in the dental sciences, osseointe-

gration has become a realized phenomenon of importance². Currently, an implant is considered as osseointegrated when there is no progressive relative movement between the implant and the bone with which it has direct contact. Essentially, the process of osseointegration reflects an anchorage mechanism whereby non-vital components can be reliably incorporated into living bone and which persist under all normal conditions of loading^{2,3}. However, the term osseointegration describes a clinical state that provides for long-term stability of a prosthesis, but this is not a biological property of any implant system or metal^{4,5}. In other words, one can claim that a "direct bone contact" as observed histologically may be indicative of the lack of a local or systemic biological response to that surface. It is therefore proposed that osseointegration is not the result of an advantageous biological tissue response but rather the lack of a negative tissue response.

Since Branemark's initial observations, the concept of osseointegration has been defined at multiple levels such as clinically⁶, anatomically², histologically, and ultrastructurally⁴. *In vivo* and *in vitro* research has also been performed to evaluate the biology of the healing response to the implant surface and how the material's characteristics, such as surface preparations, chemical composition, coatings and sterilization procedures may affect the short- and long-term stability of the metallo-biological interface⁷⁻¹⁰.

The rationale of this review is to discuss the basic scientific work performed on the concept of biology of osseointegration and the specific factors as they may relate to osseous healing around an implant.

Dr Parvizi is a consultant for Stryker Orthopaedics and has intellectual properties of Smart Tech. All other authors have no conflict of interest.

Corresponding author: George C. Babis, M.D., D.Sc., First Department of Orthopaedics, Athens University Medical School, Athens, Greece
E-mail: gebabis@med.uoa.gr george.babis@gmail.com

Accepted 3 February 2009

Tissue response to implantation

Bone healing around implants involves a cascade of cellular and extracellular biological events that take place at the bone-implant interface until the implant surface appears finally covered with a newly formed bone¹¹. These biological events include the activation of osteogenetic processes similar to those of the bone healing process, at least in terms of initial host response^{3,12,13}. This cascade of biological events is regulated by growth and differentiation factors released by the activated blood cells at the bone-implant interface¹⁴.

The response of the skeleton to trauma has been well studied mechanically and histologically with increasing interest in the molecular biology of this phenomenon. The host response after implantation is modified by the presence of the implant and its characteristics, the stability of the fixation and the intraoperative heating injuries that include death of osteocytes extending 100-500 μm into the host bone^{3,11-13}.

Major stages of skeletal response to implantation-related injury and key histological events as related to the host response after insertion and mechanical fixation of cementless implants include hematoma formation and mesenchymal tissue development, woven bone formation through the intramembranous pathway, and lamellar bone formation on the spicules of woven bone. The first biological component to come into contact with an endosseous implant is blood. Blood cells including red cells, platelets, and inflammatory cells such as polymorphonuclear granulocytes and monocytes emigrate from post-capillary venues, and migrate into the tissue surrounding the implant. The blood cells entrapped at the implant interface are activated and release cytokines and other soluble, growth and differentiation factors¹⁴.

Initial interactions of blood cells with the implant influence clot formation. Platelets undergo morphological and biochemical changes as a response to the foreign surface including adhesion, spreading, aggregation, and intracellular biochemical changes such as induction of phosphotyrosine, intracellular calcium increase, and hydrolysis of phospholipids. The formed fibrin matrix acts as a scaffold (osteoconduction) for the migration of osteogenic cells and eventual differentiation (osteoinduction) of these cells in the healing compartment. Osteogenic cells form osteoid tissue and new trabecular bone that eventually remodels into lamellar bone in direct contact with most of the implant surface (osseointegration)¹⁴⁻¹⁶.

Osteoblasts and mesenchymal cells seem to migrate and attach to the implant surface from day one after implantation, depositing bone-related proteins and creating a non-collagenous matrix layer on the implant surface that regulates cell adhesion and binding of minerals. This matrix is an early-formed calcified afibrillar layer on the implant surface, involving poorly mineralized osteoid similar to the bone cement lines and laminae limitans that forms a continuous, 0.5 mm thick layer that is rich in calcium, phosphorus, osteopontin and bone sialoprotein^{16,17}.

Peri-implant osteogenesis

Peri-implant osteogenesis can be *in distance* and *in contact* from the host bone. Distance osteogenesis refers to the newly formed peri-implant bone trabeculae that develop from the host bone cavity towards the implant surface. In contrast, contact osteogenesis refers to the newly formed peri-implant bone that develops from the implant to the healing bone. The newly formed network of bone trabeculae ensures the biological fixation of the implant and surrounds marrow spaces containing many mesenchymal cells and wide blood vessels. A thin layer of calcified and osteoid tissue is deposited by osteoblasts directly on the implant surface. Blood vessels and mesenchymal cells fill the spaces where no calcified tissue is present^{14,18,19}.

Murai et al. were the first to report a 20-50 μm thin layer of flat osteoblast-like cells, calcified collagen fibrils and a slight mineralized area at a titanium implant-bone interface¹⁷. The newly formed bone was laid down on the reabsorbed surface of the old bone after osteoclastic activity. This suggested that the implant surface is positively recognizable from the osteogenic cells as a biomimetic scaffold which may favor early peri-implant osteogenesis. Cement lines of poorly mineralized osteoid demarcated the area where bone reabsorption was completed and bone formation initiated. A few days after implantation, even osteoblasts in direct contact with the implant surface began to deposit collagen matrix directly on the early formed cement line/lamina limitans layer on the implant surface. Osteoblasts cannot always migrate so rapidly to avoid being completely enveloped by the mineralizing front of calcifying matrix; these osteoblasts became clustered as osteocytes in bone lacunae¹⁷.

The early deposition of new calcified matrix on the implant surface is followed by the arrangement of the woven bone and bone trabeculae. This is appropriate for the peri-implant bone healing process as it shows a very active wide surface area, contiguous with marrow spaces rich in vascular and mesenchymal cells. Marrow tissue containing a rich vasculature supports mononuclear precursors of osteoclasts so bone trabeculae remodel faster than cortical bone¹⁹.

Initially, rapid woven bone formation occurs on implants to restore continuity, even though its mechanical competence is lower compared to lamellar bone based on the random orientation of its collagen fibers. Woven and trabecular bone fill the initial gap at the implant-bone interface. Arranged in a three-dimensional regular network, it offers a high resistance to early implant loading. Its physical architecture including arches and bridges offers a biological scaffold for cell attachment and bone deposition that is biological fixation^{19,20}. The early peri-implant trabecular bone formation ensures tissue anchorage that corresponds to biological fixation of the implant. This begins at 10 to 14 days after surgery. Biological fixation differs from primary (mechanical) stability that is easily obtained during the implant insertion. Biological fixation of the implant involves biophysical conditions such as primary stability that is implant mechani-

cal fixation, bio-mimetic implant surface and right distance between the implant and the host bone. It is prevalently observed in rough implant surfaces¹⁹. Next, woven bone is progressively remodeled and substituted by lamellar bone that may reach a high degree of mineralization. At three months post-implantation, a mixed bone texture of woven and lamellar matrix can be found around different types of titanium implants (Figure 1)^{3,21}.

Peri-implant bone contains regular osteons and host bone chips enveloped in mature bone. The implant surface is covered with flattened cells. The bone-implant interface shows inter-trabecular marrow spaces delimited by titanium surface from one side and by newly formed bone from the other one rich in cells and blood vessels¹⁹. Host bone chips between the implant and the host bone cavity presumably occur from the surgical bur preparation or implant insertion. These are enveloped in a newly formed peri-implant trabecular bone, and seem to be involved in trabecular bone formation during the first weeks, i.e., in the biological fixation of the implant, by improving and guiding peri-implant osteogenesis as osteoconductive and osteoinductive biological material. Therefore, it may be useful in clinical practice not washing with a saline solution or aspirating the bone cavity before or during the implant insertion²².

From the implant side an oxidation of metallic implants has been described both *in vitro* and *in vivo*³. Cementless fixation of a joint replacement implant occurs in the context of the surgical trauma created at the time of implantation. In contrast to cemented fixation, in which interdigitation of cement and the surrounding trabecular bone provides a degree of fixation, with cementless fixation the connection occurs at the implant's surface via newly formed bone tissue. Successful cementless fixation depends on the establishment and maintenance of a durable connection between the implant and host skeleton^{23,24}.

Major factors for the failure of peri-implant osteogenesis include the decreased number and/or activity of osteogenic cells, the increased osteoclastic activity, the imbalance between anabolic and catabolic local factors acting on bone formation and remodeling, the abnormal bone cell proliferation rate and response to systemic and local stimuli and mechanical stress, and the impaired vascularization of the peri-implant tissue²⁵. Vascularization is of critical importance for the process of osseointegration. Differentiation of osteogenic cells strictly depends on tissue vascularity. Ossification is also closely related to the revascularization of the differentiating tissue. Since aging impairs angiogenesis, biomaterial osseointegration is also reduced. In the elderly, the association of impaired angiogenesis with osteoporosis increases the implant failure risk²⁵.

Peri-implant bone remodeling

Bone in contact with the implant surface undergoes morphological remodeling as adaptation to stress and mechanical loading. The turnover of peri-implant mature bone in

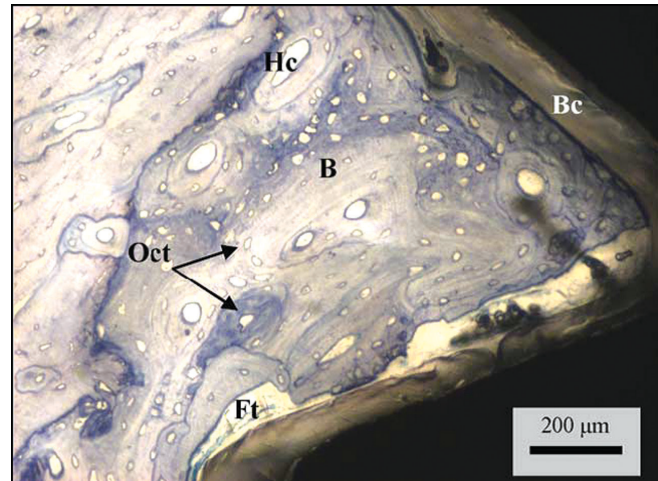


Figure 1. Photomicrograph taken by a light microscope at a high magnification. Newly formed bone (B) in direct contact with the implant, osteocytes (Oct) cells, Haversian canal (Hc) and some fibrous tissues (Ft). The biomimetic coating (Bc) can be observed in the implant's surface. (Reprinted from Publication: *Materials Science and Engineering C*, 24, ECS Rigo, AO Boschi, M Yoshimoto, S Allegrini Jr, B Konig Jr, MJ Carbonari, "Evaluation *in vitro* and *in vivo* of biomimetic hydroxyapatite coated on titanium dental implants", 647-651, Copyright (2004), with permission from Elsevier).

osseointegrated implants is confirmed by the presence of medullary or marrow spaces containing osteoclasts, osteoblasts, mesenchymal cells and lymphatic/blood vessels next to the implant surface. During the remodeling of the peri-implant bone, new osteons circle around the implant with their long axes parallel to the implant surface and perpendicular to the long axis of the implants. Osteoid tissue is produced by osteoblasts suggesting that osteogenesis is underway. The remodelled bone can extend up to 1 mm from the implant surface^{19,21}.

Factors affecting osseointegration

Various factors may enhance or inhibit osseointegration. Factors enhancing osseointegration include implant-related factors such as implant design and chemical composition, topography of the implant surface, material, shape, length, diameter, implant surface treatment and coatings²⁵, the status of the host bone bed and its intrinsic healing potential²⁶, the mechanical stability and loading conditions applied on the implant¹³, the use of adjuvant treatments such as bone grafting, osteogenic biological coatings and biophysical stimulation²⁷⁻²⁹, and pharmacological agents such as simvastatin and bisphosphonates^{30,31}.

Factors inhibiting osseointegration include excessive implant mobility and micromotion^{32,33}, inappropriate porosity of the porous coating of the implant³⁴, radiation therapy^{35,36} and pharmacological agents such as cyclosporin A,

methotrexate and cis-platinum³⁷⁻³⁹, warfarin and low molecular weight heparins⁴⁰, non-steroid anti-inflammatory drugs especially selective COX-2 inhibitors^{41,42}, and patients' related factors such as osteoporosis, rheumatoid arthritis, advanced age, nutritional deficiency, smoking and renal insufficiency⁴³⁻⁴⁶.

The different materials, shape, length, diameter, implant surface treatment and coatings have been proposed to enhance clinical performance. The biocompatibility of the material is of great importance and a predictor of osseointegration, as it is essential to establish stable fixation with direct bone-implant contact and no fibrous tissue at the interface⁴⁷. Titanium is widely used as an orthopaedic implant material; its advantages include high biocompatibility, increased resistance to corrosion, and lack of toxicity on macrophages and fibroblasts, and diminished inflammatory response in peri-implant tissues. Its surface is composed of an oxide layer that provides the ability to repair itself by reoxidation when damaged^{48,49}. Other materials have also been proposed either as an alternative to titanium or as alloy systems, including tantalum, aluminum, niobium, nickel, zirconium, and hafnium⁵⁰⁻⁵⁴.

Inappropriate porosity of the porous coating of an implant also inhibits bone ingrowth. Narrow pore throats have been found to inhibit tissue differentiation in pores, possibly because of inadequate vascularization³⁴. Porous tantalum is a low modulus metal with a characteristic appearance similar to cancellous bone⁵⁵. The biomaterial properties of porous tantalum include the high volumetric porosity (70-80%), low modulus of elasticity, high frictional characteristics, and excellent biocompatibility. *In vitro* studies have shown osteoblast growth and differentiation related to porous tantalum implants. A bone-like apatite coating-scaffold formation has been observed with excellent bone and soft tissue ingrowth properties^{56,57}. Early clinical studies in patients having total hip arthroplasty using porous tantalum implants reveal a high rate of radiographic and histological bone ingrowth, improved clinical indices and no evidence of wear and osteolysis. In revision total hip arthroplasty with or without tantalum augments, early reports are associated with excellent results regarding osseointegration and stability. Porous tantalum has also been used in primary and revision total knee arthroplasty⁵⁸⁻⁶².

Modifications of metal surfaces often are employed as a means of controlling tissue-titanium interactions and shortening the time of bone fixation⁶³. Cells at the interface and their secreted proteins involved in the process of osseointegration alter the structure and physiochemical properties of the implant surface. Continuous electrochemical events at the tissue-implant interface are related to metal ions released into tissue; these ions are traced in the peri-implant tissues or other organs, in the patient's serum and urine. Excessive metal ion release has been shown *in vitro* to inhibit cell function and apatite formation²².

Appropriate surface characteristics for osseointegration include pore size and interconnectedness in the case of

macro-textured surfaces, surface roughness in the case of micro-textured surfaces, and surface chemistry in the case of ceramic coated surfaces⁶⁴. Implant surfaces and types can be divided into roughened and coated such as titanium plasma-sprayed or hydroxyapatite-coated, machine-processed such as machined or polished, and no coated such as sand-blasted, acidetched or anodically roughened⁶⁵⁻⁶⁸.

In vitro, different surface micro-topographies were found to modulate bone cell differentiation and mineralization in monolayer fetal rat calvarial cell cultures on titanium implant materials⁶⁹. The roughness-dependent regulation of osteoblast proliferation, differentiation and local factor production is related to the activation of integrin receptors by substrate, thus regulating phosphokinase C and A through phospholipase C and A2 pathways⁷⁰. Rough surfaces favor osseointegration through platelets and monocytes adhesion⁶⁴, enhancement of direct osteoblast attachment and subsequent proliferation and differentiation⁷¹, and enlargement of the implant area in contact with the host bone favoring primary stability⁶⁷. In smooth implant surfaces distance osteogenesis is more prevalent, while in rough implant surfaces both distance and contact osteogenesis are present²². In general, moderately rough surfaces favor peri-implant bone growth better than smoother or rougher surfaces⁷². Among different pore sizes, a pore size above 80 μm is associated with improved bone ingrowth in both hydroxyapatite and tricalcium phosphate materials⁷³.

A healthy bone bed with minimal surgical trauma is important since it is the source of cells, local regulatory factors, nutrients, and vessels that contribute to the bone healing response. The implantation site influences the osseointegration process through different levels of bone cellularity and vascularity⁷⁴. A high-quality bone also seems to be important for the initial implant stability⁷⁵.

To obtain implant osseointegration, primary mechanical stability of the implant is essential, especially in one-stage surgical procedures. Primary mechanical stability consists of rigid fixation between the implant and the host bone cavity with no micro-motion of the implant or minimal distortional strains. Excessive implant motion or poor implant stability results in tensile and shear motions, stimulating a fibrous membrane formation around the implant and causing displacement at the bone-implant interface, thus inhibiting osseointegration and leading to aseptic loosening and failure of the implant^{32,33,76}. Primary stability depends on the surgical technique, implant design, and implantation site. Cortical bone allows a higher mechanical anchorage to the implant than cancellous bone. Primary stability limits micro-motion of the implant in the early phases of tissue healing and favors successful osseointegration⁷⁷.

Mechanical stress and implant micro-motion are associated with implant osseointegration or failure. In a study, 20 microns of oscillating displacement was compatible with stable bone ingrowth with high interface stiffness, whereas 40 and 150 microns of motion were not²⁴. Implant loading leads to micro-motion at the bone-implant interface. Some degree

of micro-motion is tolerated. Within certain limits, mechanical loading stimulates bone formation⁷⁸. Bone formation is also a function of biomechanical effects. The spherical stress/strain tensors regulate the speed of biochemical processes and the deviator of stress/strain tensors initiate the biochemical reactions⁷⁹. Osseointegration was observed in the presence of elastic interface micro-motions of up to 30 μm , whereas micro-motions larger than 150 μm were reported to compromise or inhibit the biological integration of the prosthesis⁸⁰⁻⁸². In general, micro-motion at the interface influences tissue differentiation and excessive micro-motion compromises implant osseointegration. The magnitude of micro-motion at the interface significantly influences tissue differentiation around immediately loaded implants (Figure 2)^{83,84}. In a randomized prospective study of 43 patients, the effect of partial and full weight-bearing after uncemented total hip arthroplasty was evaluated using radiostereometric analysis. No adverse effects such as stem migration and rotation, cup translation and rotation, and femoral head penetration-wear were observed in patients instructed for full weight-bearing⁸⁵. Currently, weight-bearing as tolerated is recommended for young patients with excellent bone quality after cementless total hip arthroplasty with a double-wedge press-fit femoral component²³.

An appropriate area between the host bone and the implant enables the migration of osteogenic cells from the bone marrow towards the implant surface, thus favoring rapid and extensive osteogenesis⁸⁶. However, when bone is in tight contact with the implant surface, only poor bone formation or even bone resorption is seen, whereas in the gap between the implant body and the host bone new bone trabeculae support the biological fixation of the implant^{15,19,87}. On the other hand, gaps exceeding 500 μm reduce the quality of the newly formed bone and delay the rate of gap filling. In addition, injuries to the pre-existing bone, due to bone heating injuries located beyond 100-500 μm , always occur during surgical preparation. It has therefore been suggested that an appropriate space between implant and host bone may be useful for early peri-implant bone formation⁸⁶.

Simvastatin is a lipid lowering agent with osteoanabolic effects. Histomorphometric studies have shown increased bone ingrowth and mechanical examination, increased interface strength, superior stability and osseous adaptation at the bone/implant interface in the simvastatin-treated group^{31,88}. Bisphosphonates inhibit osteoclast-mediated bone resorption and normalize the high rate of bone turnover that characterizes osteoporosis. Consequently, there is a rationale for using bisphosphonates to enhance early stability of implants in patients with low bone mass^{30,62,89-92}.

Cyclooxygenase-2 (COX-2) selective inhibitors non-steroid anti-inflammatory drugs (NSAIDs) given continuously for 6 weeks in an animal model yielded statistically less bone ingrowth compared to the control treatment. However, when given during the initial or final 2 weeks, it did not appear to interfere with bone ingrowth^{93,94}. Celecoxib does not seem to inhibit bone ingrowth or bone formation, when

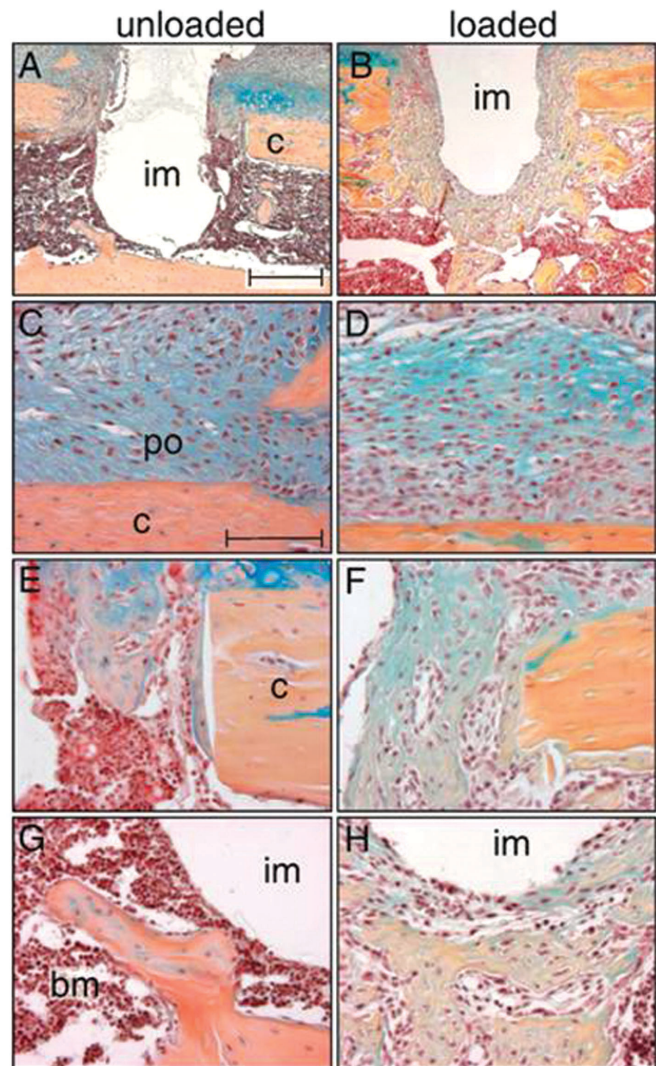


Figure 2. Micromotion of 150 μm axial displacement of the implant induces exuberant bone formation in gap and bone marrow compartments. (A) Seven days after implant placement in an unloaded environment, bone formation occurred in the gap region, but not in the bone marrow cavity. (B) In contrast, micro-motion induced a dramatic increase in bone formation in the gap and bone marrow cavity. High magnification of the periosteum showed that in both the unloaded (C) and loaded cases (D), cells started to proliferate and to differentiate into either chondrocytes or osteoblasts. (E) About half of the gap region in unloaded implants was filled with a bony matrix, (F) whereas micro-motion resulted in a nearly complete osseous fill of the gap. (G) The bone marrow cavity surrounding the unloaded implant lacked significant, newly deposited osseous matrix. (H) The most robust result accompanying a physical stimulus occurred in the marrow cavity, where exuberant bone formation encapsulated most of the implant. Abbreviations: b: bone marrow; c: cortex; im: implant; po: periosteum. Scale bar in A, B: 300 μm , C-H: 100 μm . (Reprinted from Publication: *Bone*, 40(4), Leucht P, Kim JB, Wazen R, Currey JA, Nanci A, Brunski JB, Helms JA, "Effect of mechanical stimuli on skeletal regeneration around implants", 919-930, Copyright (2007), with permission from Elsevier).

taken as part of a peri-operative pain relief protocol in staged bilateral total knee arthroplasty. Meloxicam negatively influenced bone healing in the cortical and cancellous bone around titanium implants inserted in rats after continuous administration^{41,42,95-97}. Also, it has been suggested that perioperative administration of indomethacin causes a transient decrease in attachment strength at early periods, but it does not seem to significantly affect long-term osseointegration of porous-coated implants⁹⁸.

The administration of warfarin was found to significantly impair both the attachment strength and the ingrowth of bone uncoated porous implants made of cobalt-chromium-molybdenum alloy; however, no such inhibitory effect was observed in hydroxyapatite-coated implants⁴⁰. Enoxaparin, dalteparin and unfractionated heparin led to a significant decrease of matrix collagen type II content and calcification in concentrations equal or higher than the therapeutic one. In contrast, fondaparinux, a synthetic anticoagulant substance similar to heparin, showed no inhibitory *in vitro* effects on human osteoblasts within the concentration range investigated (0.01-100 µg/ml). Therefore, fondaparinux may be used to avoid the heparin-related negative influence on osteoblast-dependent fracture healing and endoprosthetic implant integration^{99,100}.

In vitro and animal research has shown slower biomaterial osseointegration and higher rate of prosthetic device failures in the presence of osteoporosis^{44,101-104}. Osteoporosis seems to compromise the biological and mechanical fixation of implants used for fracture fixation and joint replacement. The increased risk of implant failure in osteoporotic bone is secondary to various factors that are present and alter its structural, biological and mechanical properties. Osteoporosis seems to affect cell proliferation, protein synthesis, cell reactivity to local factors, and mesenchymal cells numbers^{46,105}. In osteoporosis, the number and activity of cells of the osteogenic lineage (mesenchymal cells and osteoblasts) is decreased, the number and activity of osteoclasts is increased, and vascularization is impaired^{11,106}. It has been shown that ovariectomized-induced osteopenia in rats impairs the osseointegration of HA-coated titanium implants and that ibandronate administered at doses analogous to those used to clinically treat osteoporosis and metabolic bone diseases counters this harmful effect. Ibandronate may, therefore, have a role in improving the osseointegration of implants in patients with osteoporosis and metabolic bone diseases¹⁰⁷.

The role of radiation therapy remains controversial; however, radiation therapy seems to delay bone remodeling pre- and post-implantation^{35,36}. Osteon formation and osseointegration is compatible with bone irradiation¹⁰⁸. After evaluation of the tissue response to bone-anchored implants retrieved from irradiated sites in patients, Bolind et al. found that it is possible to achieve bone anchorage of implants in irradiated tissue, but they did not conclude on radiation dose and bone tissue response¹⁰⁹.

Iliac bone marrow grafting has been used to enhance bone ingrowth into the porous coating of tibial components in

total knee arthroplasty. Decreased incidence of radiolucent lines has been observed when iliac marrow grafting was used, suggesting that it enhances biological fixation in porous coated implants¹¹⁰. Demineralized bone matrix (DBM) has also been used to enhance osseointegration on porous implants. However, in the presence of a good bone-implant interference fit, there is no beneficial effect in applying DBM gel to a porous-coated or hydroxyapatite-coated porous implant surface. The small amount that can be applied and the degree of osteoinductive properties of DBM seem to preclude it from having a significant biological effect¹¹¹.

Because of autologous bone graft harvesting-related complications and its limited available quantity of autologous bone graft, bone allograft and bone graft substitutes, and "biological" coatings have been used to induce osseointegration^{28,29}. Hydroxyapatite coating on metallic implant devices offers the possibility of combining the strength of the metals with the bioactivity of the ceramics. Different techniques of preparation include ion sputtering, plasma spray, sol-gel, electrodeposition and a biomimetic process. Calcium phosphate ceramics may increase the protein adsorption on the implant surface favoring both the platelet adhesion-activation and fibrin binding by accelerating implant healing and they increase the implant surface³.

Several growth and differentiation factors have been used either alone or combined as biocoatings of conventional implants to accelerate and enhance the bone ingrowth and to strengthen implant fixation. These factors include the bone morphogenetic proteins (BMPs), in particular BMP-2 and BMP-7 or osteogenic protein-1 (OP-1), and growth factors such as platelet-derived growth factor (PDGF), insulin-like growth factor (IGF), and transforming growth factor-beta 1 (TGFβ-1) alone or combined with IGF-1, and TGFβ-2. Other biological coatings that have been used to improve osseointegration of titanium implants include collagen and other extracellular matrix proteins such as fibronectin and vitronectin¹¹²⁻¹¹⁵, and systemic administration of pharmacological agents such as ibandronate and human parathyroid hormone 1-34^{116,117}.

Coating endosseous implants with growth factors such as BMPs may be one way to accelerate and/or enhance the quality of osseointegration¹¹⁸. High doses of OP-1 resulted in inhibition of fibrous tissue formation, which, however, did not seem to promote bone formation¹¹⁹. In an acetabulum model, no effect of OP-1 was found on the incorporation of impacted bone grafts¹²⁰. Recently, cell-mediated regional gene therapy was introduced to deliver potent morphogens or growth factors in regenerative medicine. Direct application of the BMP-2 gene using a liposomal vector enhanced bone regeneration in a bony defect; gene delivery combined with bone grafting could induce rapid osseointegration of the bone-implant interface at an earlier stage¹²¹.

BMP-2 can also increase new bone formation synergistically with FGF and IGF-1 to improve bone-implant osseointegration. The combination of BMP-2 and b-FGF showed faster growth of new bone at 8 months¹²².

Gene expression has been identified around titanium implants in *in vivo* bone healing in an animal model using DNA microarray; 86 genes were up-regulated (more than two-fold) in the implant-healing group compared to the osteotomy-healing group as a control. The up-regulated genes included collagenous and non-collagenous extracellular matrix-related genes, proteoglycans and bone resorption-related genes¹²³.

Conclusion

Cell types, implant and bone tissues, growth factors and cytokines are involved in a co-ordinated manner during the inflammatory, formation and remodeling phases of bone healing²⁶. This means that osseointegration should be regarded not as an exclusive reaction to a specific implant material but as the expression on the endogenous basic regenerative potential of bone. The final goal is controlled, guided, and rapid peri-implant bone healing which leads to fine and fast osseointegration for direct structural and functional connection between living bone and the surface of an implant into bone allowing early implant loading. A better understanding of the complex biological events occurring at the bone-implant interface will ultimately lead to improved biologically-driven design strategies for endosseous implants.

References

1. Brånemark PI. Vital microscopy of bone marrow in rabbit. *Scand J Clin Lab Invest* 1959;11(Suppl.38):1-82.
2. Brånemark PI. Osseointegration and its experimental studies. *J Prosthet Dent* 1983;50:399-410.
3. Rigo ECS, Boschi AO, Yoshimoto M, Allegrini S Jr, König B Jr, Carbonari MJ. Evaluation *in vitro* and *in vivo* of biomimetic hydroxyapatite coated on titanium dental implants. *Mater Sci Eng C* 2004;24:647-51.
4. Linder L, Albrektsson T, Brånemark PI, Hansson HA, Ivarsson B, Jönsson U, Lundström I. Electron microscopic analysis of the bone-titanium interface. *Acta Orthop Scand* 1983;54:45-52.
5. Stanford CM, Keller JC. The concept of osseointegration and bone matrix expression. *Crit Rev Oral Biol Med* 1991;2:83-101.
6. Adell R, Lekholm U, Rockler B, Brånemark PI. A 15-year study of osseointegrated implants in the treatment of the edentulous jaw. *Int J Oral Surg* 1981;10:387-416.
7. Stanford CM, Keller JC, Solursh M. Bone cell expression on titanium surfaces is altered by sterilization treatments. *J Dent Res* 1994;73:1061-71.
8. Swart KM, Keller JC, Wightman JP, Draughn RA, Stanford CM, Michaels CM. Short-term plasma-cleaning treatments enhance *in vitro* osteoblast attachment to titanium. *J Oral Implantol* 1992;18:130-7.
9. Keller JC, Draughn RA, Wightman JP, Dougherty WJ, Meletiou SD. Characterization of sterilized CP titanium implant surfaces. *Int J Oral Maxillofac Implants* 1990;5:360-7.
10. Michaels CM, Keller JC, Stanford CM. *In vitro* periodontal ligament fibroblast attachment to plasma-cleaned titanium surfaces. *J Oral Implantol* 1991;17:132-9.
11. Fini M, Giavaresi G, Torricelli P, Borsari V, Giardino R, Nicolini A, Carpi A. Osteoporosis and biomaterial osseointegration. *Biomed Pharmacother* 2004;58:487-93.
12. Soballe K, Hansen ES, Brockstedt-Rasmussen H, Bünger C. Hydroxyapatite coating converts fibrous tissue to bone around loaded implants. *J Bone Joint Surg Br* 1993;75:270-8.
13. Soballe K. Hydroxyapatite ceramic coating for bone implant fixation. Mechanical and histological studies in dogs. *Acta Orthop Scand Suppl* 1993;255:1-58.
14. Davies JE. Mechanisms of endosseous integration. *Int J Prosthodont* 1998;11:391-401.
15. Berglundh T, Abrahamsson I, Lang NP, Lindhe J. *De novo* alveolar bone formation adjacent to endosseous implants. *Clin Oral Implants Res* 2003;14:251-62.
16. Meyer U, Joos U, Mythili J, Stamm T, Hohoff A, Fillies T, Stratmann U, Wiesmann HP. Ultrastructural characterization of the implant/bone interface of immediately loaded dental implants. *Biomaterials* 2004;25:1959-67.
17. Murai K, Takeshita F, Ayukawa Y, Kiyoshima T, Suetsugu T, Tanaka T. Light and electron microscopic studies of bone-titanium interface in the tibiae of young and mature rats. *J Biomed Mater Res* 1996;30:523-33.
18. Gailit J, Clark RA. Wound repair in the context of extracellular matrix. *Curr Opin Cell Biol* 1994;6:717-25.
19. Franchi M, Fini M, Martini D, Orsini E, Leonardi L, Ruggeri A, Giavaresi G, Ottani V. Biological fixation of endosseous implants. *Micron* 2005;36:665-71.
20. Probst A, Spiegel HU. Cellular mechanisms of bone repair. *J Invest Surg* 1997;10:77-86.
21. Chappard D, Aguado E, Huré G, Grizon F, Basle MF. The early remodeling phases around titanium implants: a histomorphometric assessment of bone quality in a 3- and 6-month study in sheep. *Int J Oral Maxillofac Implants* 1999;14:189-96.
22. Franchi M, Bacchelli B, Martini D, Pasquale VD, Orsini E, Ottani V, Fini M, Giavaresi G, Giardino R, Ruggeri A. Early detachment of titanium particles from various different surfaces of endosseous dental implants. *Biomaterials* 2004;25:2239-46.
23. Bottner F, Zawadsky M, Su EP, Bostrom M, Palm L, Ryd L, Sculco TP. Implant migration after early weight-bearing in cementless hip replacement. *Clin Orthop Relat Res* 2005;436:132-7.
24. Bragdon CR, Burke D, Lowenstein JD, O'Connor DO, Ramamurti B, Jasty M, Harris WH. Differences in stiffness of the interface between a cementless porous implant and cancellous bone *in vivo* in dogs due to varying amounts of implant motion. *J Arthroplasty* 1996;

- 11:945-51.
25. Marco F, Milena F, Gianluca G, Vittoria O. Peri-implant osteogenesis in health and osteoporosis. *Micron* 2005;36:630-44.
 26. Linder L, Obrant K, Boivin G. Osseointegration of metallic implants. II. Transmission electron microscopy in the rabbit. *Acta Orthop Scand* 1989;60:135-9.
 27. Khan SN, Cammisa FP Jr, Sandhu HS, Diwan AD, Girardi FP, Lane JM. The biology of bone grafting. *J Am Acad Orthop Surg* 2005;13:77-86.
 28. Arrington ED, Smith WJ, Chambers HG, Bucknell AL, Davino NA. Complications of iliac crest bone graft harvesting. *Clin Orthop* 1996;329:300-9.
 29. Younger EM, Chapman MW. Morbidity at bone graft donor sites. *J Orthop Trauma* 1989;3:192-5.
 30. Eberhardt C, Habermann B, Müller S, Schwarz M, Bauss F, Kurth AH. The bisphosphonate ibandronate accelerates osseointegration of hydroxyapatite-coated cementless implants in an animal model. *J Orthop Sci* 2007;12:61-6.
 31. Basarir K, Erdemli B, Can A, Erdemli E, Zeyrek T. Osseointegration in arthroplasty: can simvastatin promote bone response to implants? *Int Orthop* 2007; [Epub ahead of print].
 32. Giori NJ, Ryd L, Carter DR. Mechanical influences on tissue differentiation at bone-cement interfaces. *J Arthroplasty* 1995;10:514-22.
 33. Pilliar RM, Lee JM, Maniopoulos C. Observations on the effect of movement on bone ingrowth into porous-surfaced implants. *Clin Orthop Relat Res* 1986; 208:108-13.
 34. Otsuki B, Takemoto M, Fujibayashi S, Neo M, Kokubo T, Nakamura T. Pore throat size and connectivity determine bone and tissue ingrowth into porous implants: three-dimensional micro-CT based structural analyses of porous bioactive titanium implants. *Biomaterials* 2006;27:5892-900.
 35. Kudo M, Matsui Y, Ohno K, Michi K. A histomorphometric study of the tissue reaction around hydroxyapatite implants irradiated after placement. *J Oral Maxillofac Surg* 2001;59:293-300.
 36. Sumner DR, Turner TM, Pierson RH, Kienapfel H, Urban RM, Liebner EJ, Galante JO. Effects of radiation on fixation of non-cemented porous-coated implants in a canine model. *J Bone Joint Surg Am* 1990; 72:1527-33.
 37. Sakakura CE, Marcantonio E Jr, Wenzel A, Scaf G. Influence of cyclosporin A on quality of bone around integrated dental implants: a radiographic study in rabbits. *Clin Oral Implants Res* 2007;8:34-9.
 38. Eder A, Watzek G. Treatment of a patient with severe osteoporosis and chronic polyarthritis with fixed implant-supported prosthesis: a case report. *Int J Oral Maxillofac Implants* 1999;14:587-90.
 39. McDonald AR, Pogrel MA, Sharma A. Effects of chemotherapy on osseointegration of implants: a case report. *J Oral Implantol* 1998;24:11-3.
 40. Callahan BC, Lisecki EJ, Banks RE, Dalton JE, Cook SD, Wolff JD. The effect of warfarin on the attachment of bone to hydroxyapatite-coated and uncoated porous implants. *J Bone Joint Surg Am* 1995;77:225-30.
 41. Dahners LE, Mullis BH. Effects of nonsteroidal anti-inflammatory drugs on bone formation and soft-tissue healing. *J Am Acad Orthop Surg* 2004;12:139-43.
 42. Pablos AB, Ramalho SA, König B Jr, Furuse C, de Araújo VC, Cury PR. Effect of meloxicam and diclofenac sodium on peri-implant bone healing in rats. *J Periodontol* 2008;79:300-6.
 43. Rosenqvist R, Bylander B, Knutson K, Rydholm U, Rooser B, Egund N, Lidgren L. Loosening of the porous coating of bicompartmental prostheses in patients with rheumatoid arthritis. *J Bone Joint Surg Am* 1986;68:538-42.
 44. Zhang H, Lewis CG, Aronow MS, Gronowicz GA. The effects of patient age on human osteoblasts' response to Ti-6Al-4V implants *in vitro*. *J Orthop Res* 2004;22:30-8.
 45. Mombelli A, Cionca N. Systemic diseases affecting osseointegration therapy. *Clin Oral Implants Res* 2006; 17(Suppl.2):97-103.
 46. Wong MM, Rao LG, Ly H, Hamilton L, Ish-Shalom S, Sturtridge W, Tong J, McBroom R, Josse RG, Murray TM. *In vitro* study of osteoblastic cells from patients with idiopathic osteoporosis and comparison with cells from non-osteoporotic controls. *Osteoporos Int* 1994; 4:21-31.
 47. Anselme K. Osteoblast adhesion on biomaterials. *Biomaterials* 2000;21:667-81.
 48. Breme J, Steinhäuser E, Paulus G. Commercially pure titanium Steinhäuser plate-screw system for maxillofacial surgery. *Biomaterials* 1988;9:310-3.
 49. Browne M, Gregson PJ. Effect of mechanical surface pretreatment on metal ion release. *Biomaterials* 2000; 21:385-92.
 50. Alberius P. Bone reactions to tantalum markers. A scanning electron microscopic study. *Acta Anat (Basel)* 1983;115:310-8.
 51. Johansson CB, Albrektsson T. A removal torque and histomorphometric study of commercially pure niobium and titanium implants in rabbit bone. *Clin Oral Implants Res* 1991;2:24-9.
 52. Kujala S, Ryhanen J, Danilov A, Tuukkanen J. Effect of porosity on the osteointegration and bone ingrowth of a weight-bearing nickel-titanium bone graft substitute. *Biomaterials* 2003;24:4691-7.
 53. Thomsen P, Larsson C, Ericson LE, Sennerby L, Lausmaa J, Kasemo B. Structure of the interface between rabbit cortical bone and implants of gold, zirconium and titanium. *J Mater Sci Mater Med* 1997;8:653-65.
 54. Mohammadi S, Esposito M, Cucu M, Ericson LE, Thomsen P. Tissue response to hafnium. *J Mater Sci Mater Med* 2001;12:603-11.
 55. Levine BR, Sporer S, Poggie RA, Della Valle CJ, Jacobs JJ. Experimental and clinical performance of

- porous tantalum in orthopedic surgery. *Biomaterials* 2006;27:4671-81.
56. Andreykiv A, Prendergast PJ, van Keulen F, Swieszkowski W, Rozing PM. Bone ingrowth simulation for a concept glenoid component design. *J Biomech* 2005;38:1023-33.
 57. Bellemans J. Osseointegration in porous coated knee arthroplasty. The influence of component coating type in sheep. *Acta Orthop Scand Suppl* 1999;288:1-35.
 58. Levine B, Sporer S, Della Valle CJ, Jacobs JJ, Paprosky W. Porous tantalum in reconstructive surgery of the knee: a review. *J Knee Surg* 2007;20:185-94.
 59. Kokubo T. Metallic materials stimulating bone formation. *Med J Malaysia* 2004;59(Suppl.B):91-2.
 60. Barrère F, van der Valk CM, Meijer G, Dalmeijer RA, de Groot K, Layrolle P. Osteointegration of biomimetic apatite coating applied onto dense and porous metal implants in femurs of goats. *Biomed Mater Res B Appl Biomater* 2003;67:655-65.
 61. Gruen TA, Poggie RA, Lewallen DG, Hanssen AD, Lewis RJ, O'Keefe TJ, Stulberg SD, Sutherland CJ. Radiographic evaluation of a monoblock acetabular component: a multicenter study with 2- to 5-year results. *J Arthroplasty* 2005;20:369-78.
 62. Garbuz DS, Hu Y, Kim WY, Duan K, Masri BA, Oxland TR, Burt H, Wang R, Duncan CP. Enhanced gap filling and osteoconduction associated with alendronate-calcium phosphate-coated porous tantalum. *J Bone Joint Surg Am* 2008;90:1090-100.
 63. Kokubo T, Kim HM, Kawashita M. Novel bioactive materials with different mechanical properties. *Biomaterials* 2003;24:2161-75.
 64. Park JY, Davies JE. Red blood cell and platelet interactions with titanium implant surfaces. *Clin Oral Implants Res* 2000;11:530-9.
 65. Kurzweg H, Heimann RB, Troczynski T, Wayman ML. Development of plasma-sprayed bioceramic coatings with bond coats based on titania and zirconia. *Biomaterials* 1998;19:1507-11.
 66. Soballe K, Overgaard S, Hansen ES, Brokstedt-Rasmussen H, Lind M, Bunger C. A review of ceramic coatings for implant fixation. *J Long Term Eff Med Implants* 1999;9:131-51.
 67. Cochran DL, Nummikoski PV, Higginbottom FL, Hermann JS, Makins SR, Buser D. Evaluation of an endosseous titanium implant with a sandblasted and acid-etched surface in the canine mandible: radiographic results. *Clin Oral Implants Res* 1996;7:240-52.
 68. Larsson C, Thomsen P, Aronsson BO, Rodahl M, Lausmaa J, Kasemo B, Ericson LE. Bone response to surface-modified titanium implants: studies on the early tissue response to machined and electropolished implants with different oxide thicknesses. *Biomaterials* 1996;17:605-16.
 69. Boyan BD, Bonewald LF, Paschalis EP, Lohmann CH, Rosser J, Cochran DL, Dean DD, Schwartz Z, Boskey AL. Osteoblast-mediated mineral deposition in culture is dependent on surface microtopography. *Calcif Tissue Int* 2002;71:519-29.
 70. Boyan BD, Sylvia VL, Liu Y, Sagun R, Cochran DL, Lohmann CH, Dean DD, Schwartz Z. Surface roughness mediates its effects on osteoblasts via protein kinase A and phospholipase A2. *Biomaterials* 1999;20:2305-10.
 71. Fini M, Giardino R. *In vitro* and *in vivo* tests for the biological evaluation of candidate orthopedic materials: benefits and limits. *J Appl Biomater* 2003;1:155-63.
 72. Albrektsson T, Wennerberg A. Oral implant surfaces: Part 2 - review focusing on clinical knowledge of different surfaces. *Int J Prosthodont* 2004;17:544-64.
 73. Galois L, Mainard D. Bone ingrowth into two porous ceramics with different pore sizes: an experimental study. *Acta Orthop Belg* 2004;70:598-603.
 74. Spadaro JA, Albanese SA, Chase SE. Electromagnetic effects on bone formation at implants in the medullary canal in rabbits. *J Orthop Res* 1990;8:685-93.
 75. Wittenberg RH, Shea M, Swartz DE, Lee KS, White AA III, Hayes WC. Importance of bone mineral density in instrumented spine fusions. *Spine* 1991;16:647-52.
 76. Carter DR, Giori NJ. Effect of mechanical stress on tissue differentiation in the bony implant bed. In: Davies JE, Albrektsson T (editors). *The bone-biomaterial interface*. University of Toronto Press, Buffalo, 1991, Vol. 2. pp. 367-375.
 77. Sennerby L, Thomsen P, Ericson LE. A morphometric and biomechanical comparison of titanium implants inserted in rabbit cortical and cancellous bone. *Int J Oral Maxillofac Implants* 1992;7:62-71.
 78. Turner CH. Three rules for bone adaptation to mechanical stimuli. *Bone* 1998;23:399-407.
 79. Petrtyl M, Danesova J. Bone modeling and bone remodeling. *Acta Bioeng Biomech* 2001;3(Suppl.2):409-14.
 80. Cameron HU, Pilliar RM, MacNab I. The effect of movement on the bonding of porous metal to bone. *J Biomed Mater Res* 1973;7:301-11.
 81. Maniatopoulos C, Pilliar RM, Smith DC. Threaded versus porous-surfaced designs for implant stabilization in bone-endodontic implant model. *J Biomed Mater Res* 1986;20:1309-33.
 82. Soballe K, Hansen ES, Brockstedt-Rasmussen H, Jørgensen PH, Bünger C. Tissue ingrowth into titanium and hydroxyapatite-coated implants during stable and unstable mechanical conditions. *J Orthop Res* 1992;10:285-99.
 83. Duyck J, Vandamme K, Geris L, Van Oosterwyck H, De Cooman M, Vandersloten J, Puers R, Naert I. The influence of micro-motion on the tissue differentiation around immediately loaded cylindrical turned titanium implants. *Arch Oral Biol* 2006;51:1-9.
 84. Leucht P, Kim JB, Wazen R, Currey JA, Nanci A, Brunski JB, Helms JA. Effect of mechanical stimuli on skeletal regeneration around implants. *Bone* 2007;

- 40:919-30.
85. Thien TM, Ahnfelt L, Eriksson M, Strömberg C, Kärrholm J. Immediate weight bearing after uncemented total hip arthroplasty with an anteverted stem: a prospective randomized comparison using radiostereometry. *Acta Orthop* 2007;78:730-8.
 86. Futami T, Fujii N, Ohnishi H, Taguchi N, Kusakari H, Ohshima H, Maeda T. Tissue response to titanium implants in the rat maxilla: ultrastructural and histochemical observations of the bone-titanium interface. *J Periodontol* 2000;71:287-98.
 87. Sandborn PM, Cook SD, Spires WP, Kester MA. Tissue response to porous-coated implants lacking initial bone apposition. *J Arthroplasty* 1988;3:337-46.
 88. Ayukawa Y, Okamura A, Koyano K. Simvastatin promotes osteogenesis around titanium implants. *Clin Oral Implants Res* 2004;15:346-50.
 89. Dayer R, Badoud I, Rizzoli R, Ammann P. Defective implant osseointegration under protein undernutrition: prevention by PTH or pamidronate. *J Bone Miner Res* 2007;22:1526-33.
 90. Chacon GE, Stine EA, Larsen PE, Beck FM, McGlumphy EA. Effect of alendronate on endosseous implant integration: an *in vivo* study in rabbits. *J Oral Maxillofac Surg* 2006;64:1005-9.
 91. Shanbhag AS. Use of bisphosphonates to improve the durability of total joint replacements. *J Am Acad Orthop Surg* 2006;14:215-25.
 92. Eberhardt C, Stumpf U, Brankamp J, Schwarz M, Kurth AH. Osseointegration of cementless implants with different bisphosphonate regimens. *Clin Orthop Relat Res* 2006;447:195-200.
 93. Hofmann AA, Bloebaum RD, Koller KE, Lahav A. Does celecoxib have an adverse effect on bone remodeling and ingrowth in humans? *Clin Orthop Relat Res* 2006;452:200-4.
 94. Goodman SB, Ma T, Mitsunaga L, Miyanishi K, Genovese MC, Smith RL. Temporal effects of a COX-2-selective NSAID on bone ingrowth. *J Biomed Mater Res A* 2005;72:279-87.
 95. Ribeiro FV, César-Neto JB, Nociti FH Jr, Sallum EA, Sallum AW, De Toledo S, Casati MZ. Selective cyclooxygenase-2 inhibitor may impair bone healing around titanium implants in rats. *J Periodontol* 2006;77:1731-5.
 96. Chikazu D, Tomizuka K, Ogasawara T, Saijo H, Koizumi T, Mori Y, Yonehara Y, Susami T, Takato T. Cyclooxygenase-2 activity is essential for the osseointegration of dental implants. *Int J Oral Maxillofac Surg* 2007;36:441-6.
 97. Lionberger DR, Noble PC. Celecoxib does not affect osteointegration of cementless total hip stems. *J Arthroplasty* 2005;20(7 Suppl.3):115-22.
 98. Cook SD, Barrack RL, Dalton JE, Thomas KA, Brown TD. Effects of indomethacin on biologic fixation of porous-coated titanium implants. *J Arthroplasty* 1995;10:351-8.
 99. Matziolis G, Perka C, Disch A, Zippel H. Effects of fondaparinux compared with dalteparin, enoxaparin and unfractionated heparin on human osteoblasts. *Calcif Tissue Int* 2003;73:370-9.
 100. Bagno A, Piovani A, Dettin M, Chiarion A, Brun P, Gambaretto R, Fontana G, Di Bello C, Palù G, Castagliuolo I. Human osteoblast-like cell adhesion on titanium substrates covalently functionalized with synthetic peptides. *Bone* 2007;40:693-9.
 101. Fini M, Nicoli Aldini N, Gandolfi MG, Mattioli Belmonte M, Giavaresi G, Zucchini C, De Benedittis A, Amati S, Ravaglioli A, Krayewski A, Rocca M, Guzzardella GA, Biagini G, Giardino R. Biomaterials for orthopedic surgery in osteoporotic bone: a comparative study in osteopenic rats. *Int J Artif Organs* 1997;20:291-7.
 102. Fini M, Giavaresi G, Torricelli P, Krajewski A, Ravaglioli A, Belmonte MM, Biagini G, Giardino R. Biocompatibility and osseointegration in osteoporotic bone. *J Bone Joint Surg Br* 2001;83:139-43.
 103. Hayashi K, Uenoyama K, Mashima T, Sugioka Y. Remodelling of bone around hydroxyapatite and titanium in experimental osteoporosis. *Biomaterials* 1994;15:11-6.
 104. Rocca M, Fini M, Giavaresi G, Nicoli Aldini N, Giardin R. Tibial implants: biomechanical and histomorphometric studies of hydroxyapatite-coated and uncoated stainless steel and titanium screws in long-term ovariectomized sheep. *Int J Artif Organs* 2001;24:649-54.
 105. D'Ippolito G, Schiller PC, Ricordi C, Roos BA, Howard GA. Age-related osteogenic potential of mesenchymal stromal stem cells from human vertebral bone marrow. *J Bone Miner Res* 1999;14:1115-22.
 106. Augat P, Simon U, Liedert A, Claes L. Mechanics and mechano-biology of fracture healing in normal and osteoporotic bone. *Osteoporos Int* 2005;16(Suppl.2):S36-43.
 107. Viera-Negrón YE, Ruan WH, Winger JN, Hou X, Sharawy MM, Borke JL. Effect of ovariectomy and alendronate on implant osseointegration in rat maxillary bone. *J Oral Implantol* 2008;34:76-82.
 108. Basseur M, Brogniez V, Gregoire V, Reychler H, Lengele B, D'Hoore W, Nyssen-Behets C. Effects of irradiation on bone remodelling around mandibular implants: an experimental study in dogs. *Int J Oral Maxillofac Surg* 2006;35:850-5.
 109. Bolind P, Johansson CB, Johansson P, Granstrom G, Albrektsson T. Retrieved implants from irradiated sites in humans: a histologic/histomorphometric investigation of oral and craniofacial implants. *Clin Implant Dent Relat Res* 2006;8:142-50.
 110. Kim KJ, Iwase M, Kotake S, Itoh T. Effect of bone marrow grafting on the titanium porous-coated implant in bilateral total knee arthroplasty. *Acta Orthop* 2007;78:116-22.
 111. Cook SD, Salkeld SL, Patron LP, Barrack RL. The

- effect of demineralized bone matrix gel on bone ingrowth and fixation of porous implants. *J Arthroplasty* 2002;17:402-8.
112. Geissler U, Hempel U, Wolf C, Scharnweber D, Worch H, Wenzel K. Collagen type I coating of Ti6Al4V promotes adhesion of osteoblasts. *J Biomed Mater Res* 2000;51:752-60.
 113. Rammelt S, Schulze E, Bernhardt R, Hanisch U, Scharnweber D, Worch H, Zwipp H, Biewener A. Coating of titanium implants with type-I collagen. *J Orthop Res* 2004;22:1025-34.
 114. Ku Y, Chung CP, Jang JH. The effect of the surface modification of titanium using a recombinant fragment of fibronectin and vitronectin on cell behaviour. *Biomaterials* 2005;26:5153-7.
 115. Frosch KH, Sondergeld I, Dresing K, Rudy T, Lohmann CH, Rabba J, Schild D, Breme J, Stuermer KM. Autologous osteoblasts enhance osseointegration of porous titanium implants. *J Orthop Res* 2003;21:213-23.
 116. Eberhardt C, Habermann B, Tiemann S, Bauss F, Kurth AA. Improvement of osseointegration of cementless metal implant under ibandronate is dose-dependent. *Bone* 2006;38:S42-S64.
 117. Gabet Y, Muller R, Levy J, Dimarchi R, Chorev M, Bab I, Kohavi D. Parathyroid hormone 1-34 enhances titanium implant anchorage in low-density trabecular bone: a correlative micro-computed tomographic and biomechanical analysis. *Bone* 2006;39:276-82.
 118. Huang YH, Polimeni G, Qahash M, Wikesjö UM. Bone morphogenetic proteins and osseointegration: current knowledge - future possibilities. *Periodontol* 2000 2008; 47:206-23.
 119. Hannink G, Aspenberg P, Schreurs BW, Buma P. High doses of OP-1 inhibit fibrous tissue ingrowth in impaction grafting. *Clin Orthop Relat Res* 2006; 452:250-9.
 120. Buma P, Arts JJ, Gardeniers JW, Verdonchot N, Schreurs BW. No effect of bone morphogenetic protein-7 (OP-1) on the incorporation of impacted bone grafts in a realistic acetabular model. *J Biomed Mater Res B Appl Biomater* 2008;84:231-9.
 121. Park J, Lutz R, Felszeghy E, Wiltfang J, Nkenke E, Neukam FW, Schlegel KA. The effect on bone regeneration of a liposomal vector to deliver BMP-2 gene to bone grafts in peri-implant bone defects. *Biomaterials* 2007;28:2772-82.
 122. Lan J, Wang Z, Wang Y, Wang J, Cheng X. The effect of combination of recombinant human bone morphogenetic protein-2 and basic fibroblast growth factor or insulin-like growth factor-I on dental implant osseointegration by confocal laser scanning microscopy. *J Periodontol* 2006;77:357-63.
 123. Kojima N, Ozawa S, Miyata Y, Hasegawa H, Tanaka Y, Ogawa T. High-throughput gene expression analysis in bone healing around titanium implants by DNA microarray. *Clin Oral Implants Res* 2008;19:173-81.