

Cortical bone response adjacent to applied light orthodontic forces in ovariectomized rats

A.I. Tsolakis¹, L. Khaldi^{2,3}, M. Makou¹, G.P. Lyritis³, M.N. Spyropoulos¹, I.A. Dontas^{3,4}

¹Department of Orthodontics, School of Dentistry, University of Athens, Greece; ²Department of Pathology, Amalia Fleming Hospital, Athens, Greece; ³Laboratory for Research of the Musculoskeletal System, School of Medicine, University of Athens, Greece; ⁴Laboratory of Experimental Surgery and Surgical Research, School of Medicine, University of Athens, Greece

Abstract

Cortical bone response to experimental orthodontic forces has not been adequately described in the available literature. The aim of this study was to investigate the application of light orthodontic forces on the cortical bone adjacent to the point of their application, in normal and ovariectomized rats. At the age of eight months, twenty-four female rats were divided equally into two groups: normal (group A) and ovariectomized (group B). A 20 gr* orthodontic force was applied to the maxillary right first molars in all animals for 14 days. Histological examination of the maxillary cortical bone, at the level of the first molar of the upper jaw, was performed on both sides of all animals. It was found that light orthodontic forces applied to the upper right first molars of normal rats result in thinner cortical bone with increased osteoblastic activity, normal lamellar orientation and normal distribution of osteocytes compared to the non-affected contralateral side. In ovariectomized rats it was found that light orthodontic forces applied to the upper right first molars result in thickening of the cortex, in comparison to the respective area of the opposite side where no orthodontic forces were applied. It seems that experimental light orthodontic forces, in rats, affect cortical bone remodeling differently, according to their hormonal status, in areas adjacent to the applied forces.

Keywords: Maxillary Cortical Bone, Light Orthodontic Forces, Ovariectomy, Rats

Introduction

Orthodontic forces may not only influence the dentoalveolar system, but also the surrounding and adjacent cortical bone. Forces applied to teeth act as a mechanical stimulus to the underlying cortical bone and when they reach certain thresholds they influence bone and/or remodeling patterns¹. In the biology of tooth movement, frontal resorption is believed to be the result of low force levels and undermining resorption is associated with high force levels. Nevertheless, the determination of a low or a high level force applied in orthodontic movement is not strict and definite. The difference between a high and a low force is relative and the ter-

minology used varies according to the reactions of the surrounding periodontium². On the other hand, osteoporosis is associated with an increased rate of bone turnover³, and the jaws and the alveolar bone are also affected⁴. Furthermore, heavy orthodontic forces applied to the upper jaw of ovariectomized rats result in a distraction-like phenomenon in maxillary bone¹. Nevertheless, the bone response to experimental orthodontic forces has not been adequately studied in the available literature.

The purpose of the present study was to investigate morphological changes in the maxillary cortical bone adjacent to the first molar, following the application of light orthodontic forces in mature normal and ovariectomized female rats.

Materials and methods

Laboratory animals

Twenty-four Wistar female rats were used in this study. The experiments took place in the Laboratory of Experimental Surgery and Surgical Research of the Medical School of the University of Athens, as well as in the Laboratory of

The authors have no conflict of interest.

Corresponding author: Apostolos I. Tsolakis, 45 Tsimiski Street, 41223 Larissa, Greece
E-mail: apostso@otenet.gr

Accepted 18 September 2008

Orthodontics of the Dental School of the University of Athens. The experimental animals were obtained from the Hellenic Pasteur Institute (Athens, Greece). The study received the permit no. K/381/6/5-7-05 from the Veterinary Directorate, according to the country's legislation (P.D. 160/91), with which it has conformed to the European Directive 86/609 regarding "the protection of vertebrate animals used in experimental and other scientific purposes".

The animals were divided into two different groups at the age of 8 months, consisting of twelve animals each, as follows: Group A included 12 rats that were subjected to orthodontic movement of the upper right first molars without any surgery. Group B included 12 rats that were subjected to orthodontic movement of the upper right first molars, having undergone bilateral ovariectomy at the age of 6 months. Bilateral ovariectomies were performed under ketamine/xylazine anaesthesia in the female rats from the ventral approach.

Orthodontic forces

Orthodontic rat molar movement was achieved by the application of a closed coil spring (0.010 X 0.045 inches) extending from the upper right first molar to the upper right central incisor. The coil spring was 1 cm in length, and its activation for 0.08 cm produced a force of 20 gr*. This force is considered a light force as analyzed in the discussion. The orthodontic force was applied for 14 days in both groups. At the end of the experimental period, the animals were euthanized, the upper jaw was dissected from the skull and the spring was carefully removed.

Histology

The specimens were fixed in 10% buffered formalin for 18 hours and decalcified in EDTA buffer for 6-8 weeks. The apical region of the maxilla was dissected sagittally to 5 mm-thick slices including the central incisor to the third molar. The specimens were then dehydrated with ethanol and embedded in paraffin. Histological sections, 4-5 μm -thick, were obtained, stained with Hematoxylin and Eosin and examined under transmitted light microscopy. The cortical bone proximal to the point of force application at the level of the upper first rat molar was examined in this study.

Results

Laboratory animals

There were no casualties following anaesthesia and the operations of ovariectomy and orthodontic force application. Less than 20% of the rats demonstrated a mild transient body weight loss during the first week of force application. No local edema was apparent after the 2nd day of the coil spring application.

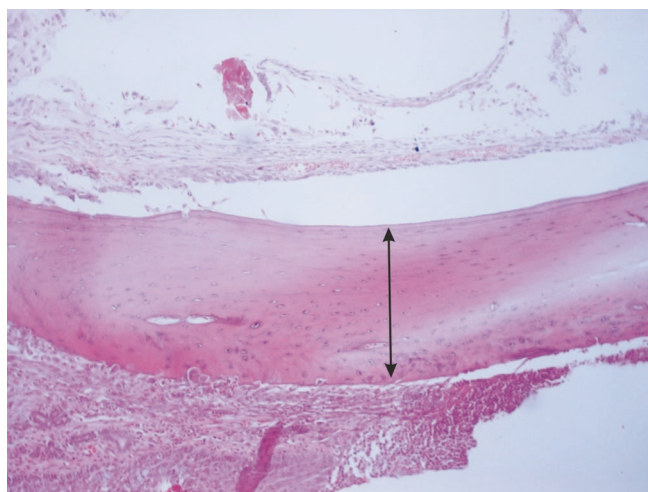


Figure 1. Cortical bone, in normal rats, at the level of the first molar, on the side where no orthodontic forces were applied. Two-headed arrow indicates cortical thickness (H/E x10 obj.).

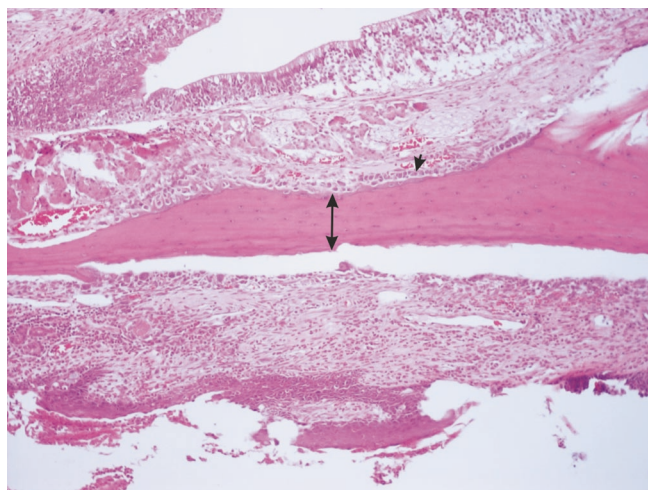


Figure 2. Cortical bone, in normal rats, at the level of the first molar, on the side where orthodontic forces were applied. Two-headed arrow indicating thinning of the cortex. Arrow pointing at osteoblastic activity H/E x10 obj.).

In normal rats (Group A)

The cortical bone of the maxilla at the level of the first molar, where no forces were applied, was thick, with obvious osteocytes and little osteoblastic and osteoclastic cellular activity on its surface (Figure 1 H/E x10 obj.). In comparison, the cortical bone on the other side of the maxilla at the level of the first molar, where orthodontic forces were applied, was thinner showing increased osteoblastic activity, but nor-

mal lamellar orientation with distribution of fewer osteocytes (Figure 2 H/E x10 obj.). Figures 1 and 2 are representative of the changes that appeared in the majority of the animals in Group A.

In ovariectomized rats (Group B)

The cortical bone of the maxilla at the level of the first molar, where no forces were applied, was thin and one third of its width was composed of woven bone with irregular cement lines, little osteoblastic and osteoclastic cellular activity, and decreased osteocytes (Figure 3 H/E x10 obj.). The cortical bone of the maxilla at the level of the first molar, where orthodontic forces were applied, revealed thickening of the cortex in comparison to the respective area of the opposite side. Half of the cortex width was composed of lamellar bone, while the rest was composed of woven bone with increased porosity. Visible irregular cement lines and little osteoblastic and osteoclastic cellular activity were apparent on the surface (Figure 4 H/E x10 obj.). The osteocytes were markedly fewer in the maxilla of both sides of the Group B animals in comparison to Group A. Figures 3 and 4 are representative of the changes that appeared in the majority of the animals in Group B.

Discussion

The present study aimed at detecting possible cortical bone changes adjacent to the molar subjected to force application caused by light orthodontic forces in osteoporotic rats. The rat animal model has been used successfully both for experimental orthodontic movement⁵ and experimental osteoporosis protocols³.

In the present study, the applied orthodontic force of 20 gr* is considered a light force. As it has been stated previously¹ a 60 gr* force applied to the rat molar may be comparable to a force of 480 gr* applied to the human molar. Consequently a 20 gr* force applied to the rat molar may be compared to a 160 gr* force applied to a human molar during orthodontic treatment. The above respective analogy may be a result of the different anatomic and functional characteristics of the two species, human and rat, as well as a result of the different forces generated from the masseter muscles and applied to the molar teeth of the two species^{6,7}. According to Ren et al.⁸, a 40 gr* force on a rat molar is comparable to a force of 2000 gr* on a human molar because a human molar is 50 times larger than a rat molar. It is difficult to agree with this statement though, since the special structural and myofunctional architecture of the rodent's stomatognathic system are not taken into account, and only the tooth size is considered.

Forces applied to individual teeth may affect not only the adjacent alveolar bone but also the adjacent cortical bone of the loaded area. Recent studies have suggested that when a bone is loaded, osteocytes sense it through the interstitial bone fluid in the canaliculae and osteocyte lacunae, and gen-

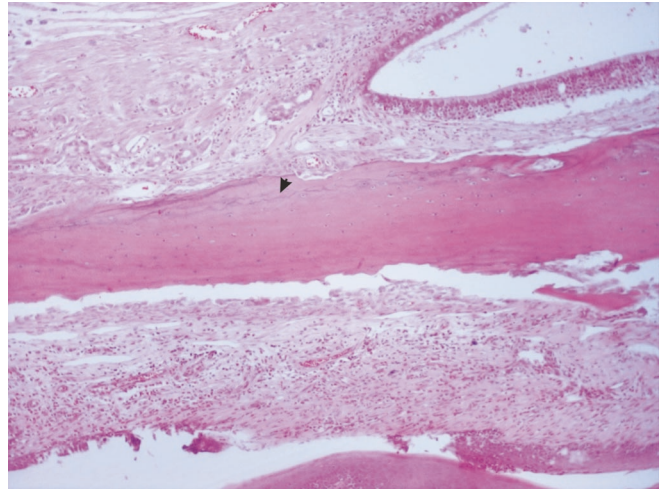


Figure 3. Cortical bone, in ovariectomized rats, at the level of the first molar, on the side where no orthodontic forces were applied. Arrow indicating irregular cement lines (H/E x10 obj.).

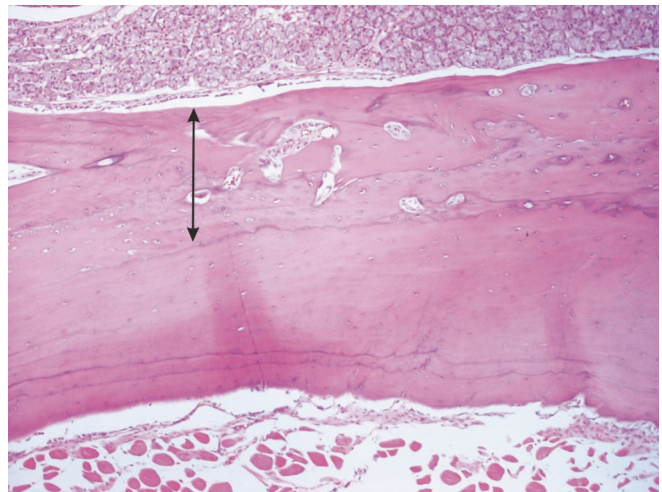


Figure 4. Cortical bone, in ovariectomized rats, at the level of the first molar, on the side where orthodontic forces were applied. Two-headed arrow indicating woven bone and increased porosity apparent in part of the cortex (H/E x10 obj.).

erate signals that may influence cells near or on a distant bone surface^{9,10}. Furthermore, there is limited information on the effect of loading on osteoporotic maxillary bone. High level experimental orthodontic forces resulted in a distraction-like phenomenon in cortical maxillary bone in rats¹. In this experiment using light level forces in experimental animals, cortical bone structural distortion was absent. In addition, bone hypertrophy and subperiosteal callus were not noticed.

The cortical bone osteogenic reaction to the 20 gr* force in the normal rats was expressed by lesser cortical bone width with increased osteoblastic activity, normal lamellar orientation and normal distribution of osteocytes. In contrast the cortical bone osteogenic reaction to the 20 gr* force in the ovariectomized rats was expressed by thickening of the cortex in comparison to the respective area of the opposite side. Also, woven bone formation was apparent due to osteoporosis and loading effects. The thickening of the loaded osteoporotic cortex is due to the force exertion. This is an interesting finding as regards to the biology of osteoporotic bone in general, since it is possible to change the osteoporotic remodeling process by the application of mechanical loading.

In conclusion, the application of light orthodontic forces on both normal and osteoporotic mature rats in the present study affects cortical bone remodeling differently, according to their hormonal status, in areas adjacent to the applied forces.

References

1. Spyropoulos MN, Tsolakis AI. Mechanobiological perspectives of tooth movement related to bone biology. *Essentials of Facial Growth*; Enlow DH, Hans MG. Second Edition Needham Press, Ann Arbor, MI 2008.
2. Melsen B, Cattaneo PM, Dalstra M, Kraft DC. The importance of force levels in relation to tooth movement. *Semin Orthod* 2007;13:220-33.
3. Jee WSS, Yao W. Overview: Animal models of osteopenia and osteoporosis. *J Musculoskelet Neuronal Interact* 2001;1:193-207.
4. von Wowern N, Gotfredsen K. Implant-supported overdentures, a prevention of bone loss in edentulous mandibles? A 5-year follow-up study. *Clin Oral Implants Res* 2001;12:19-25.
5. Rygh P, Moyers RE. Force Systems and Tissue Responses to Forces in Orthodontics and Facial Orthopedics. In: Moyers RE, editor. *Handbook of Orthodontics*. 4th ed. Chicago: Year Book Medical Publishers; 1988 p. 306-31.
6. Weijs WA, Dantuma R. Electromyography and mechanics of mastication in the albino rat. *J Morphol* 1976;146:1-34.
7. Pruijm GJ, De Jongh HJ, Ten Bosch JJ. Forces acting on the mandible during bilateral static bite at different bite force levels. *J Biomechanics* 1980;13:755-63.
8. Ren Y, Maltha JC, Kuijpers-Jagtman AM. The rat as a model for orthodontic tooth movement – a critical review and a proposed solution. *Eur J Orthod* 2004;26:483-90.
9. Frost HM. The mechanical bone signals; the RAP. In: *The Utah paradigm of skeletal physiology*. International Society of Musculoskeletal and Neuronal Interactions, Athens, Greece, pp. 136-140, 2004.
10. Gluhak-Heinrich J, Gu S, Pavlin D, Jiang JX. Mechanical loading stimulates expression of connexin 43 in alveolar bone cells in the tooth movement model. *Cell Commun Adhes* 2006;13:115-25.