

Vitamin K therapy for cortical bone fragility caused by reduced mechanical loading in a child with hemiplegia

T. Sugiyama^{1,2,4}, T. Takaki³, T. Saito³, T. Taguchi¹

¹Department of Orthopaedic Surgery, Yamaguchi University School of Medicine, Yamaguchi, Japan;

²Department of Orthopaedic Surgery, Tsuzumigaura Handicapped Children's Hospital, Yamaguchi, Japan;

³Applied Medical Engineering Science, Graduate School of Medicine, Yamaguchi University, Yamaguchi, Japan;

⁴Present address: Department of Veterinary Basic Sciences, The Royal Veterinary College, University of London, Royal College Street, London NW1 0TU, UK

Abstract

Fractures frequently occur at cortical bone sites in children with cerebral palsy, but there is no established therapy. We previously found that treatment with vitamins D and K increased cortical bone mass in children with severe physical disability, and have hypothesized that vitamin K could play a significant role in pediatric cortical bones under conditions with reduced mechanical loading. In the present case report, we treated a right hemiplegic ambulant eight-year-old boy with oral vitamin K (15 mg per day) for eight months. Cortical bone geometries at mid-diaphyseal sites in bilateral tibiae were evaluated before and after the treatment. The cross-sectional total, bone and marrow areas of non-hemiplegic tibia increased by 8.8%, 7.4% and 12.0%, respectively, while those of hemiplegic tibia changed by 9.0%, 14.9% and -3.4%, respectively. As a result, the polar moment of inertia, an indicator of the resistance to torsion forces, increased by 13.0% in the non-hemiplegic tibia and by 63.7% in the hemiplegic tibia. Vitamin K may restrict cortical bone fragility, caused by reduced mechanical loading, through its actions at the endosteal bone marrow interface. Further studies are needed to confirm these findings and to clarify the mechanisms involved.

Keywords: Vitamin K, Reduced Mechanical Loading, Cortical Bone, Bone Geometry, Bone Marrow

Introduction

The skeleton adapts to its mechanical circumstances and thus reduced loading results in fragile bones¹; indeed, fractures are a common problem in children with cerebral palsy². In these pediatric patients, spontaneous fractures frequently occur at the diaphyses of long bones which consist of cortical bone³. Although treatments that improve trabecular bone status are available, there is currently no established method that can be used to limit cortical bone fragility in children with physical disability. Intravenous bisphosphonate, for example, resulted in a marked improvement of areal bone

mineral density in the distal femur but its efficacy at the femoral diaphyseal cortex was insignificant⁴, which is consistent with experimental findings in rats^{5,6}. The application of low-magnitude high-frequency mechanical stimuli also produced an improvement in trabecular volumetric bone mineral density in the proximal tibia but did not induce significant beneficial change at the tibial diaphyseal cortex^{7,8}.

Bone is a rich source of vitamin K⁹ and accumulating evidence indicates that vitamin K affects bone fragility¹⁰⁻¹³. Although there have been very few clinical reports investigating the effects of vitamin K therapy on the growing skeleton¹⁴, we previously found that combined treatment with vitamins D (alfacalcidol) and K (menatetrenone [menaquinone-4]) increased second metacarpal cortical bone mass in children with severe physical disability^{15,16}. As alfacalcidol has been used for the management of bone fragility in children with cerebral palsy for over 10 years in Japan but its effect on the second metacarpal cortical bone mass is limited, we have hypothesized that vitamin K could play a significant role in pediatric skeletal health under conditions with reduced mechanical loading.

The authors have no conflict of interest.

Corresponding author: Toshihiro Sugiyama, M.D., Ph.D., Department of Veterinary Basic Sciences, The Royal Veterinary College, University of London, Royal College Street, London NW1 0TU, UK
E-mail: tsugiyama@rvc.ac.uk

Accepted 30 January 2007

	Right hemiplegic tibia			Left non-hemiplegic tibia		
	before	after	%change	before	after	%change
Total area (mm ²)	146.2	159.3	+9.0	203.0	220.8	+8.8
Bone area (mm ²)	98.9	113.6	+14.9	140.3	150.7	+7.4
Marrow area (mm ²)	47.3	45.7	-3.4	62.6	70.2	+12.0
Cross-sectional moment of inertia						
around an anterior-posterior axis (mm ⁴)	1491	3142	+110.8	2727	2936	+7.7
around a medial-lateral axis (mm ⁴)	1680	2048	+21.9	4121	4802	+16.5
Polar moment of inertia (mm ⁴)	3171	5190	+63.7	6848	7738	+13.0

Table 1. Cortical bone geometry at mid-diaphyseal sites in right hemiplegic and left non-hemiplegic tibiae before and after eight-month vitamin K treatment in an eight-year-old boy.

Methods

An eight-year-old boy had right hemiplegia caused by fetal porencephaly and had been ambulatory occasionally using canes. The hemiplegic ankle joint had shown a slight equinus contracture and the patient had received a right short leg brace; the hemiplegic leg had not been fully weight-bearing. He had received physiotherapy once a week, but had no other disease and had taken no other medication. There was no fracture history. After informed consent was obtained from his parents, we treated the patient with vitamin K (Glakay capsule [15 mg of menatetrenone]; Eisai Co., Ltd., Japan), a drug approved for the treatment of osteoporosis in Japan, for eight months from March to November in 2005 at the Tsuzumigaura Handicapped Children's Hospital. One vitamin K capsule was given orally within 30 minutes after a meal once a day.

Before and after vitamin K treatment, plain radiography of bilateral legs was performed, and precise axial high-resolution computed tomography (CT) images (0.5-mm slice thickness) at mid-diaphyseal sites in bilateral tibiae were obtained by scanning at 120 kV and 200 mA (Asteion, Toshiba Medical Systems Corporation, Japan) in order to evaluate cortical bone geometry. Considering the different lengths of hemiplegic and non-hemiplegic legs, CT scans of hemiplegic and non-hemiplegic tibiae were separately performed to measure the exact middles of each tibia. CT images were converted to monochromes by Adobe Photoshop software, and the cross-sectional total, bone and marrow areas were measured using ImageJ software (<http://rsb.info.nih.gov/ij/>). Cross-sectional moment of inertia (CSMI), an indicator of the resistance to bending forces, around anterior-posterior and medial-lateral axes was calculated using Microsoft Visual C++ software, based on the parallel-axis theorem¹⁷ as follows:

$$\text{CSMI} = \sum_{i=1}^n (wh^3/12 + whd_i^2),$$

where w and h are the width and height of each pixel in the images, respectively, and d_i is the distance from the neutral axis for pixel number i . The polar moment of inertia (PMI), an indicator of the resistance to torsion forces, was calculated as the sum of the CSMI around the anterior-posterior and medial-lateral axes. The muscle and subcutaneous fat areas were also evaluated.

Results

Prior to treatment with vitamin K, the size of the right hemiplegic tibia was smaller than that of the left non-hemiplegic tibia, and the outer cross-sectional shape of the left tibia was triangular while that of the right tibia was more rounded (Figure 1). The cross-sectional total, bone and marrow areas of the right hemiplegic tibia were only 72.0%, 70.5% and 75.6% of the left non-hemiplegic tibia, respectively. Accordingly, the CSMI around the anterior-posterior and medial-lateral axes in the hemiplegic tibia were 54.7% and 40.8% of those in the non-hemiplegic tibia. The PMI in the hemiplegic tibia was also lower (46.3%) than that in the non-hemiplegic tibia. The lengths of the hemiplegic and non-hemiplegic tibiae were 230 mm and 238 mm, respectively.

Treatment with vitamin K for eight months showed no side effects and the compliance was more than 95%. There were no changes in the physiotherapy from the preceding six months to the end of the study period. The percentage increase in the cross-sectional bone area of the right hemiplegic tibia was twice that observed in the left non-hemiplegic tibia (Table 1). This was mainly the product of a divergence in changes in the area of marrow; with the right hemiplegic marrow area decreasing (by 3.4%), while the left non-hemiplegic marrow area increased (by 12.0%) during the time of treatment. The percentage increases in the right and left total areas were similar. As a result, the percentage increase in the CSMI around the anterior-posterior axis of the hemiplegic tibia was more than 10 times higher than in the non-hemiplegic tibia. In contrast, the CSMI around the medial-lateral axis did not show such a change. The percentage increase in the PMI of the hemiplegic tibia was also approximately 5 times higher than in the non-hemiplegic tibia. The lengths of the hemiplegic and non-hemiplegic tibiae were 245 mm and 249 mm, respectively.

The muscle area of the right hemiplegic leg was smaller than that of the left non-hemiplegic leg while subcutaneous fat areas of bilateral legs were similar (Figure 2), and no significant changes were observed in these tissues after the eight-month study period.

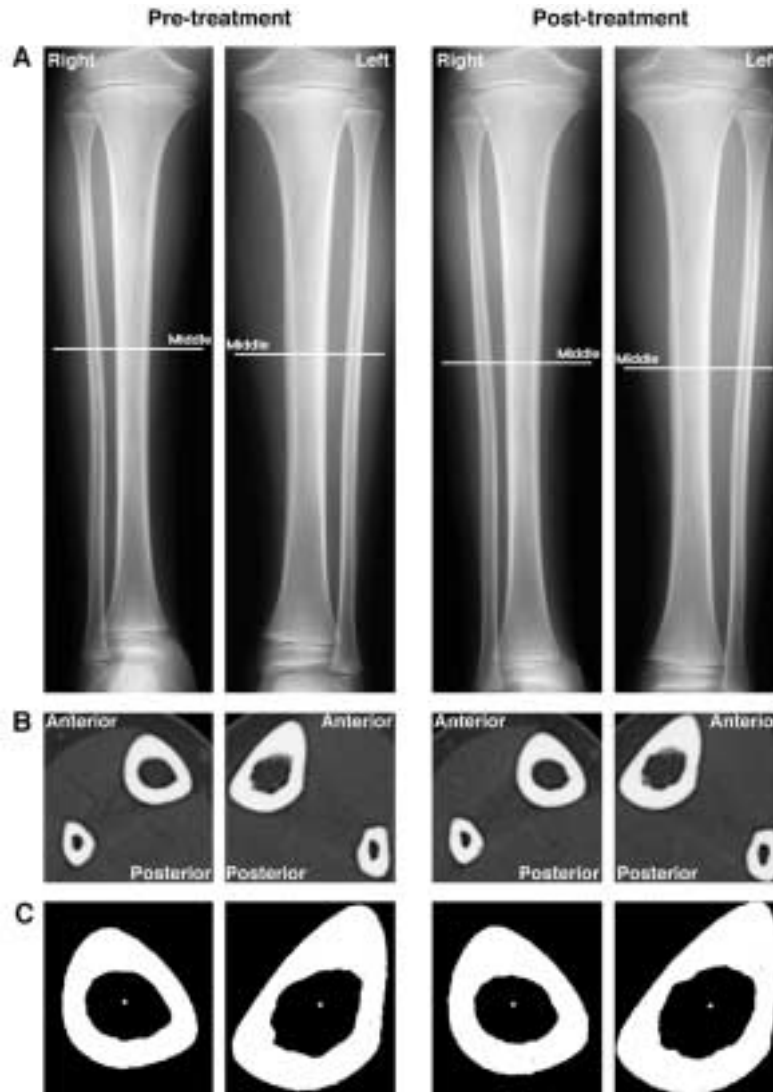


Figure 1. Effects of eight-month vitamin K treatment on right hemiplegic and left non-hemiplegic tibiae in an eight-year-old boy. (A) X-ray photographs of legs. (B) Axial computed tomography images at mid-diaphyseal sites in each tibia. (C) Monochrome images of the tibiae. White spots demarcate position of the centroid.

Discussion

In the present case, vitamin K treatment markedly improved cortical bone geometric strength of the hemiplegic tibia. This improvement was associated with periosteal and endocortical bone apposition and resulted mainly from the latter, while an equivalent endocortical change was not observed in the non-hemiplegic tibia. Consistent with our hypothesis, the inner and outer cortical bone apposition observed in the hemiplegic tibia is similar to our previous findings in second metacarpal bones treated with vitamins D and K in children with severe physical disability^{15,16}. Interestingly, the results in the hemiplegic tibia are consistent with recent experimental findings in sciatic neurectomized rats, where vitamin K treatment increased periosteal bone formation and suppressed endocortical bone resorption¹⁸.

Furthermore, a previous randomized prospective 12-month trial in hemiplegic adult stroke patients showed that second metacarpal cortical bone mass on the hemiplegic side increased by 4.3% in a vitamin K (45 mg per day)-treated group and decreased by 4.7% in an untreated group while that on the non-hemiplegic side decreased by 0.9% in the vitamin K-treated group and by 2.7% in the untreated group¹⁹. Thus, vitamin K appears to be especially efficacious for hemiplegic cortical bones in both children and adults.

The mechanisms by which vitamin K improved cortical bone geometric strength of the hemiplegic tibia of our patient remain unclear, but it is possible that vitamin K acts on bone marrow cells because of the marked induction of endocortical bone apposition. Interestingly, reduced mechanical loading has been reported to inhibit osteogenic differentiation and to promote adi-

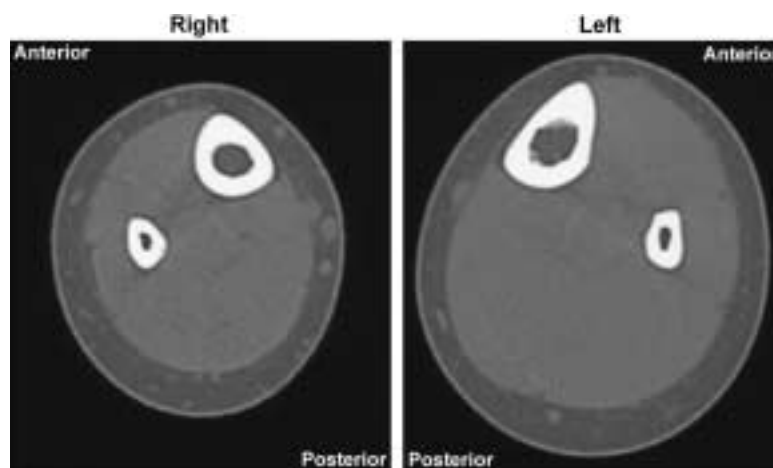


Figure 2. Bilateral axial computed tomography images at the level of mid-diaphyseal sites in each tibia in an eight-year-old boy with right hemiplegia.

pogenesis and osteoclastogenesis in bone marrow²⁰⁻²², and orally administered vitamin K distributes highly in this region²³. Thus, one possible mechanism is that vitamin K stimulates osteoblastogenesis and inhibits adipogenesis and osteoclastogenesis in bone marrow cells²⁴⁻²⁷. Notably, previous findings suggest that human bone marrow cells are indeed more sensitive to vitamin K compared with mouse bone marrow cells²⁷. On the other hand, periosteal bone expansion during growth is an important factor which acts to strengthen bones especially in the male^{28,29}, and vitamin K increases 1,25-dihydroxyvitamin D₃-induced mineralization by human periosteal osteoblasts *in vitro*³⁰. In the present case, increases in the cross-sectional total areas of hemiplegic and non-hemiplegic tibiae were similar during the time of treatment, suggesting that vitamin K promoted periosteal bone formation under conditions with reduced mechanical loading. As 1,25-dihydroxyvitamin D₃ increases the metabolism of vitamin K in human osteoblasts³¹, combination with vitamins D and K rather than vitamin K alone may be more efficacious for the promotion of periosteal bone formation^{15,16}. Finally, as vitamin K also plays specific roles in the nervous system^{32,33}, it remains possible that vitamin K affects bone metabolism by unknown mechanisms through this system. This possibility is strengthened by the apparent difference in the effects of vitamin K treatment in the hemiplegic and non-hemiplegic tibiae.

In conclusion, vitamin K therapy might restrict unloading-induced increases in cortical bone fragility possibly through its actions in bone marrow. This vitamin has a very wide safety range for patients who are not taking warfarin, a vitamin K antagonist, and could be useful for children with physical disability. Our findings agree with the reduced bone mass in children with long-term warfarin therapy³⁴; however, vitamin K³⁵ as well as warfarin^{36,37} have only a weak effect on bone mass in elderly people. Further studies are required to clarify the mechanisms by which vitamin K affects the skeleton in both children and adults.

Acknowledgements

We thank Shinya Kawai (Yamaguchi University School of Medicine) for support of our study, Masanobu Ishimaru (Tsuzumigaura Handicapped Children's Hospital, Japan) for computed tomography scanning, and Stephen Hodges (University College London, UK), Andrew Pitsillides and Robin Soper (The Royal Veterinary College, UK) for critically reading the manuscript. Toshihiro Sugiyama is a recipient of a Research Fellowship of the Uehara Memorial Foundation.

References

1. Ehrlich PJ, Lanyon LE. Mechanical strain and bone cell function: a review. *Osteoporos Int* 2002; 13:688-700.
2. Ward KA, Caulton JM, Adams JE, Mughal MZ. Perspective: cerebral palsy as a model of bone development in the absence of postnatal mechanical factors. *J Musculoskelet Neuronal Interact* 2006; 6:154-159.
3. Sugiyama T, Taguchi T, Kawai S. Spontaneous fractures and quality of life in cerebral palsy. *Lancet* 2004; 364:28.
4. Grissom LE, Kecskemethy HH, Bachrach SJ, McKay C, Harcke HT. Bone densitometry in pediatric patients treated with pamidronate. *Pediatr Radiol* 2005; 35:511-517.
5. Kodama Y, Nakayama K, Fuse H, Fukumoto S, Kawahara H, Takahashi H, Kurokawa T, Sekiguchi C, Nakamura T, Matsumoto T. Inhibition of bone resorption by pamidronate cannot restore normal gain in cortical bone mass and strength in tail-suspended rapidly growing rats. *J Bone Miner Res* 1997; 12:1058-1067.
6. Iwamoto J, Seki A, Takeda T, Sato Y, Yamada H. Effects of risedronate on femoral bone mineral density and bone strength in sciatic neurectomized young rats. *J Bone Miner Metab* 2005; 23:456-462.
7. Ward K, Alsop C, Caulton J, Rubin C, Adams J,

- Mughal Z. Low magnitude mechanical loading is osteogenic in children with disabling conditions. *J Bone Miner Res* 2004; 19:360-369.
8. Sugiyama T, Kawai S. Vibration and components of bone strength. *J Bone Miner Res* 2004; 19:1557.
 9. Hodges SJ, Bejui J, Leclercq M, Delmas PD. Detection and measurement of vitamins K₁ and K₂ in human cortical and trabecular bone. *J Bone Miner Res* 1993; 8:1005-1008.
 10. Vermeer C, Shearer MJ, Zittermann A, Bolton-Smith C, Szulc P, Hodges S, Walter P, Rambeck W, Stocklin E, Weber P. Beyond deficiency: potential benefits of increased intakes of vitamin K for bone and vascular health. *Eur J Nutr* 2004; 43:325-335.
 11. Iwamoto J, Takeda T, Sato Y. Effects of vitamin K₂ on osteoporosis. *Curr Pharm Des* 2004; 10:2557-2576.
 12. Kaneki M, Hosoi T, Ouchi Y, Orimo H. Pleiotropic actions of vitamin K: protector of bone health and beyond? *Nutrition* 2006; 845-852.
 13. Cockayne S, Adamson J, Lanham-New S, Shearer MJ, Gilbody S, Torgerson DJ. Vitamin K and the prevention of fractures: systematic review and meta-analysis of randomized controlled trials. *Arch Intern Med* 2006; 166:1256-1261.
 14. Cashman KD. Vitamin K status may be an important determinant of childhood bone health. *Nutr Rev* 2005; 63:284-289.
 15. Sugiyama T, Tanaka H, Kawai S. Vitamin K plus vitamin D treatment of bone problems in a child with skeletal unloading. *J Bone Miner Res* 1999; 14:1466-1467.
 16. Sugiyama T, Saito Y, Kaichi I, Sugi M, Tanaka H, Kawai S. Menatetrenone plus alfacalcidol treatment for bone problems in eight children with skeletal unloading. *J Bone Miner Metab* 2000; 18:41-44.
 17. Turner CH, Burr DB. Basic biomechanical measurements of bone: a tutorial. *Bone* 1993; 14:595-608.
 18. Iwamoto J, Yeh JK, Takeda T. Effect of vitamin K₂ on cortical and cancellous bones in orchidectomized and/or sciatic neurectomized rats. *J Bone Miner Res* 2003; 18:776-783.
 19. Sato Y, Honda Y, Kuno H, Oizumi K. Menatetrenone ameliorates osteopenia in disuse-affected limbs of vitamin D- and K-deficient stroke patients. *Bone* 1998; 23:291-296.
 20. Sakata T, Sakai A, Tsurukami H, Okimoto N, Okazaki Y, Ikeda S, Norimura T, Nakamura T. Trabecular bone turnover and bone marrow cell development in tail-suspended mice. *J Bone Miner Res* 1999; 14:1596-1604.
 21. Ahdjoudj S, Lasmoles F, Holy X, Zerath E, Marie PJ. Transforming growth factor β 2 inhibits adipocyte differentiation induced by skeletal unloading in rat bone marrow stroma. *J Bone Miner Res* 2002; 17:668-677.
 22. Meyers VE, Zayzafoon M, Douglas JT, McDonald JM. RhoA and cytoskeletal disruption mediate reduced osteoblastogenesis and enhanced adipogenesis of human mesenchymal stem cells in modeled microgravity. *J Bone Miner Res* 2005; 20:1858-1866.
 23. Sano Y, Tadano K, Kaneko K, Kikuchi K, Yuzuriha T. Distribution of menaquinone-4, a therapeutic agent for osteoporosis, in bone and other tissues of rats. *J Nutr Sci Vitaminol* 1995; 41:499-514.
 24. Akiyama Y, Hara K, Tajima T, Murota S, Morita I. Effect of vitamin K₂ (menatetrenone) on osteoclast-like cell formation in mouse bone marrow cultures. *Eur J Pharmacol* 1994; 263:181-185.
 25. Takeuchi Y, Suzawa M, Fukumoto S, Fujita T. Vitamin K₂ inhibits adipogenesis, osteoclastogenesis, and ODF/RANKL ligand expression in murine bone marrow cell cultures. *Bone* 2000; 27:769-776.
 26. Palacios VG, Morita I, Murota S. Expression of adipogenesis markers in a murine stromal cell line treated with 15-deoxy $\Delta^{12,14}$ -prostaglandin J₂, interleukin-11, 9-cis retinoic acid and vitamin K₂. *Prostaglandins Leukot Essent Fatty Acids* 2001; 65:215-221.
 27. Koshihara Y, Hoshi K, Okawara R, Ishibashi H, Yamamoto S. Vitamin K stimulates osteoblastogenesis and inhibits osteoclastogenesis in human bone marrow cell culture. *J Endocrinol* 2003; 176:339-348.
 28. Seeman E. Pathogenesis of bone fragility in women and men. *Lancet* 2002; 359:1841-1850.
 29. Allen MR, Hock JM, Burr DB. Periosteum: biology, regulation, and response to osteoporosis therapies. *Bone* 2004; 35:1003-1012.
 30. Koshihara Y, Hoshi K, Ishibashi H, Shiraki M. Vitamin K₂ promotes $1\alpha,25(\text{OH})_2\text{vitaminD}_3$ -induced mineralization in human periosteal osteoblasts. *Calcif Tissue Int* 1996; 59:466-473.
 31. Miyake N, Hoshi K, Sano Y, Kikuchi K, Tadano K, Koshihara Y. $1,25\text{-Dihydroxyvitamin D}_3$ promotes vitamin K₂ metabolism in human osteoblasts. *Osteoporos Int* 2001; 12:680-687.
 32. Tsang CK, Kamei Y. Novel effect of vitamin K₁ (phylloquinone) and vitamin K₂ (menaquinone) on promoting nerve growth factor-mediated neurite outgrowth from PC12D cells. *Neurosci Lett* 2002; 323:9-12.
 33. Li J, Lin JC, Wang H, Peterson JW, Furie BC, Furie B, Booth SL, Volpe JJ, Rosenberg PA. Novel role of vitamin K in preventing oxidative injury to developing oligodendrocytes and neurons. *J Neurosci* 2003; 23:5816-5826.
 34. Barnes C, Newall F, Ignjatovic V, Wong P, Cameron F, Jones G, Monagle P. Reduced bone density in children on long-term warfarin. *Pediatr Res* 2005; 57:578-581.
 35. Sugiyama T. Possible involvements of vitamin K in bone quality. *Arch Intern Med* 2007; 167:93-94.
 36. Caraballo PJ, Gabriel SE, Castro MR, Atkinson EJ, Melton LJ III. Changes in bone density after exposure to oral anticoagulants: a meta-analysis. *Osteoporos Int* 1999; 9:441-448.
 37. Eastell R. Does warfarin increase the risk of osteoporotic fracture? *Nat Clin Pract Endocrinol Metab* 2006; 2:484-485.