

Original Article

Acoustic Radiation Force Impulse (ARFI) Elastography as a diagnostic and monitoring tool for Bell's palsy: A Prospective Study

Murat Toprak¹, Nurşen Toprak², Mehmet Reşit Oncu³, Abdussamet Batur⁴, Abdullah Yılgor⁵, Nazım Bozan⁶

¹Department of Physical Medicine and Rehabilitation, Medical Faculty of Van Yüzüncü Yıl University, Turkey;

²Department of Radiology, Medical Faculty of Van Yüzüncü Yıl University, Turkey;

³Department of Emergency Medicine, Medical Faculty of Van Yüzüncü Yıl University, Turkey;

⁴Department of Radiology, Medical Faculty of Mardin Artuklu University, Mardin, Turkey;

⁵Department of Neurology, Medical Faculty of Van Yüzüncü Yıl University, Turkey;

⁶Department of Otorhinolaryngology, Medical Faculty of Van Yüzüncü Yıl University, Turkey

Abstract

Objective: To evaluate ARFI elastography as a diagnostic and monitoring tool in Bell's palsy by comparing affected and unaffected facial muscles, pre- and post-treatment. **Methods:** Thirty patients with Bell's palsy (17 females and 13 males, mean age 44.6 ± 16.76 , range: 18–72 years) were assessed using Clinical (House-Brackmann grading), electrophysiologic (EMG), and ultrasonographic (ARFI-elastography). In order to assess the diagnostic value of elastosonography, we compared the scores between the paretic and nonparetic sides of the face. Measurements were obtained bilaterally at baseline and after four weeks of physical therapy. **Results:** The initial degree of facial nerve paralysis was 5.13 ± 0.89 on the House-Brackmann scale (range 4–6). This parameter significantly decreased after the treatment, measuring 2.53 ± 0.81 . Post-treatment, significant improvements were observed in EMG and ARFI values, particularly in the orbicularis oculi and masseter muscles. No significant correlation was found between EMG and ARFI elastographic parameters. **Conclusions:** ARFI elastography is a promising, non-invasive tool for monitoring Bell's palsy recovery, though standardization is needed.

Keywords: Acoustic radiation force impulse, Bell's palsy, Elastography, Electromyography, Rehabilitation

Introduction

Bell's palsy (BP) is the most common cause of lower motor neuron facial palsy, accounting for about 70% of cases of unilaterally facial nerve paralysis¹. The incidence of this condition ranges between 11.5 to 53.3 cases per 100,000 individuals². Approximately 30% of patients with

Bell's palsy may experience lingering consequences, known as sequelae³. Common treatments include corticosteroids, antiviral drugs, physical therapy and surgery^{1,4}.

The diagnosis of BP is determined by reviewing epidemiological data and medical history and conducting a physical examination⁵. Objective and subjective methods have been developed for this assessment based on the presence or absence of pre-established facial movements⁶. The House-Brackmann (HB) grading system is commonly used to diagnose and monitor Bell's palsy but is subjective^{6,7}. Objective tests, such as electromyography (EMG), can provide valuable insights to guide the management and expectations of patients with Bell's palsy⁷. However, it is invasive, painful, and of limited use in clinical practice, considering that the equipment is found only in a few institutions⁸. Therefore, innovative non-invasive tools that can be used in an office setting are needed.

The authors have no conflict of interest.

Corresponding author: Murat Toprak, Medical Faculty of Van Yüzüncü Yıl University, Department of Physical Medicine and Rehabilitation, 65080 Van, Turkey

E-mail: dr.murattoprak@gmail.com • murattoprak@yyu.edu.tr
ORCID: 0000-0002-6490-4645

Edited by: G. Lyritis

Accepted 4 December 2025



Currently, there is no reliable test available to accurately predict the outcome of cases related to BP. Recently, elastography (ES) has gained popularity in biomedical research and shows promise in physical therapy and rehabilitation⁹. Compression elastography, acoustic radiation force impulse (ARFI), and shear wave elastography (SWE) are commonly used for this purpose^{10,11}. A paucity of studies has been reported in the literature regarding the use of quantitative muscle ultrasound as a standardized tool for measuring facial muscle characteristics in patients diagnosed with Bell's palsy^{12,13}. No previous study has investigated the efficacy of elastosonography as a monitoring tool for Bell's palsy rehabilitation.

To our knowledge, this is the first study to evaluate the feasibility of ARFI elastosonography in Bell's palsy rehabilitation. The objective of the study was to evaluate the changes in facial muscle stiffness in patients diagnosed with Bell's palsy, both in the acute phase of the condition and following a period of rehabilitation.

Materials and Methods

Subjects and Study Design

Between May 2018 and June 2020, 30 patients with Bell's palsy were included in the study at the Van Yüzüncü Yil University Hospital Physical Therapy and Rehabilitation Clinic, Van, Türkiye.

Clinical evaluation

Data collected: age, sex, BMI, education, affected side, symptom duration, treatment, and systemic diseases (e.g., hypertension, diabetes, thyroid disorders). The House-Brackmann facial nerve function grading system was used to evaluate patients before and after treatment. The House-Brackmann grading system consists of six grades: I (normal function), II (mild dysfunction), III (moderate), IV (moderately severe), V (severe dysfunction), and VI (total paralysis).

The examiners were not given any information about the patient's initial characteristics. At the beginning, all the participants were assessed, and their HB grades were recorded. EMG assessment was performed on the orbicularis oculi and nasalis muscles, both before and after treatment. Two expert sonographers performed facial muscle ultrasonography on the exact dates as examinations HB and EMG. Ultrasonography was used to evaluate the thickness of the masseter muscle, and elastosonography was used to measure the stiffness of both the orbicularis oculi, nasalis, and masseter muscles. Before and after treatment, the measurements were taken separately on both the affected and unaffected sides. The unaffected side of patients with Bell's palsy was used as the control group. The masseter muscle was used as a bilateral reference muscle to establish reference data for adjacent muscles not innervated by the facial nerve.

Inclusion criteria

The study recruited patients aged 18 to 72 with House-Brackmann grade (HB) IV to VI. All patients received a diagnosis from the Department of Otolaryngology at Van YYU Medical Faculty Hospital. Medications were immediately taken within the first few weeks. Patients were eligible if they were graded at House-Brackmann grade 4 or higher.

Exclusion criteria

Patients with stroke, embolism, or thrombosis, a history of trauma or surgery, infectious diseases, unregulated diabetes mellitus, psychiatric disorders, any other muscular neurological disorders, or those who refused study participation were excluded from the study. We also excluded Bell's Palsy patients with a disease course exceeding 1 year.

Treatment program

The treatment program consisted of daily 30-minute sessions, five days per week for four weeks, involving electrical stimulation (delivering 100 ms rectangular pulses at one pulse per second for 30-100 contractions per session), hot packs (20- minutes), and facial exercises on the affected side. Participants were instructed to perform a few facial exercises, including tightly closing their eyes, frowning, raising eyebrows, blinking, contracting the nose, kissing, blowing air, smiling, pouting, and inflating the cheeks (2 times per day, each movement 8 times).

Electrodiagnostic methods

Needle electromyography was used in these evaluations. An electrical stimulus was delivered to the stylomastoid foramen to activate the ipsilateral facial nerve. The EMG method used two electrodes on the nose and lips to find the maximum CMAP. One electrode functions as a reference electrode, while the other serves as a recording electrode. The same methodology is repeated to obtain a compound muscle action potential (CMAP) of the contralateral, unparalyzed side. Two mimetic muscles were examined: the orbicularis oculi and the nasalis. The orthodromic method was used to measure the nerve conduction velocity. The nerve conduction test used supramaximal intensity to achieve the highest amplitude. The definition of any axonal pathology in the nerves was that the motor nerve action potential amplitude was reduced. The amplitude (mV), latency (ms), and velocity (m/s) values were compared for each nerve. Facial motor nerve conduction tests were performed on the face at a temperature of 34°C, while the room was kept at 22-24°C. The electrophysiological examination was conducted using a Medelec Synergy instrument manufactured by Oxford Instruments in Surrey, UK.

Ultrasound (US) and ARFI elastographic technique

Two radiologists performed the ultrasound measurements and ARFI-elastography with a decade of experience. The subjects were examined in the supine position on an ultrasound platform. The facial muscles on both sides were scanned in all patients, who were in a supine position with their heads turned to the opposite side from the scanned side. The transducer was consistently positioned at a 90-degree angle to the skin surface. Individuals were allowed to lie comfortably on the examination table in the supine position. The US probe was placed in the axial plane in the area where the masseter, orbicularis oculi and nasalis muscles are located, respectively. ARFI measurements were obtained for the masseter and orbicularis oculi; nasalis was assessed by EMG only. First, the masseter muscle thickness was measured. Subsequent to the US examination, ARFI elastography was conducted with the patient and probe in the same position as delineated above. Three measurements were taken for each facial muscle at rest, and the averages were used. Shear wave velocity (SWV) was expressed in m/s. The measurements that did not meet the required standard were then repeated. The ARFI elastography method was utilized to assess the elasticity of the masseter and orbicularis oculi muscles. ARFI imaging-based SWE was applied using the virtual touch tissue imaging quantification (VTIQ) option on a 4–9 MHz 9L4 linear transducer. US- and ARFI-based elastography examinations were performed using a Siemens ACUSON S2000™ (Siemens Healthcare, Erlangen, Germany). All the ultrasound images were saved in the DICOM format. In the study, numerical results were the sole evaluation metric, with no color-coded maps (Figure 1).

Intra-operator and inter-operator variability analysis

For the purpose of intra-operator reliability, measurements were repeated two hours later by the same radiologist. To assess inter-operator variability, measurements were performed by a different radiologist with 12 years' experience in conventional US and 5 years' experience in ARFI-elastography after the first radiologist. Fifteen individuals from the healthy control group and 15 individuals from the study group were randomly selected for intra-operator and inter-operator variability analysis.

Statistical Analysis

Sample size: We estimated the required sample using $n = (Z_{1-\alpha/2})^2 \cdot \sigma^2 / \delta^2$ for a two-sided $\alpha = 0.05$, assuming $\sigma = 0.5$ (ARFI SWV) and a target difference $\delta = 0.18$ (m/s). With $Z_{1-\alpha/2} = 1.96$, this yields $n \approx 30$ ($1.96^2 \cdot 0.5^2 / 0.18^2 = 29.64$). We report Cohen's d as the standardized mean difference using the pooled standard deviation for between- and pre- and post-comparisons.

The data expressed as the mean \pm standard deviation, or n (%). The student t -test was used to compare group means. The normality assumption of the continuous

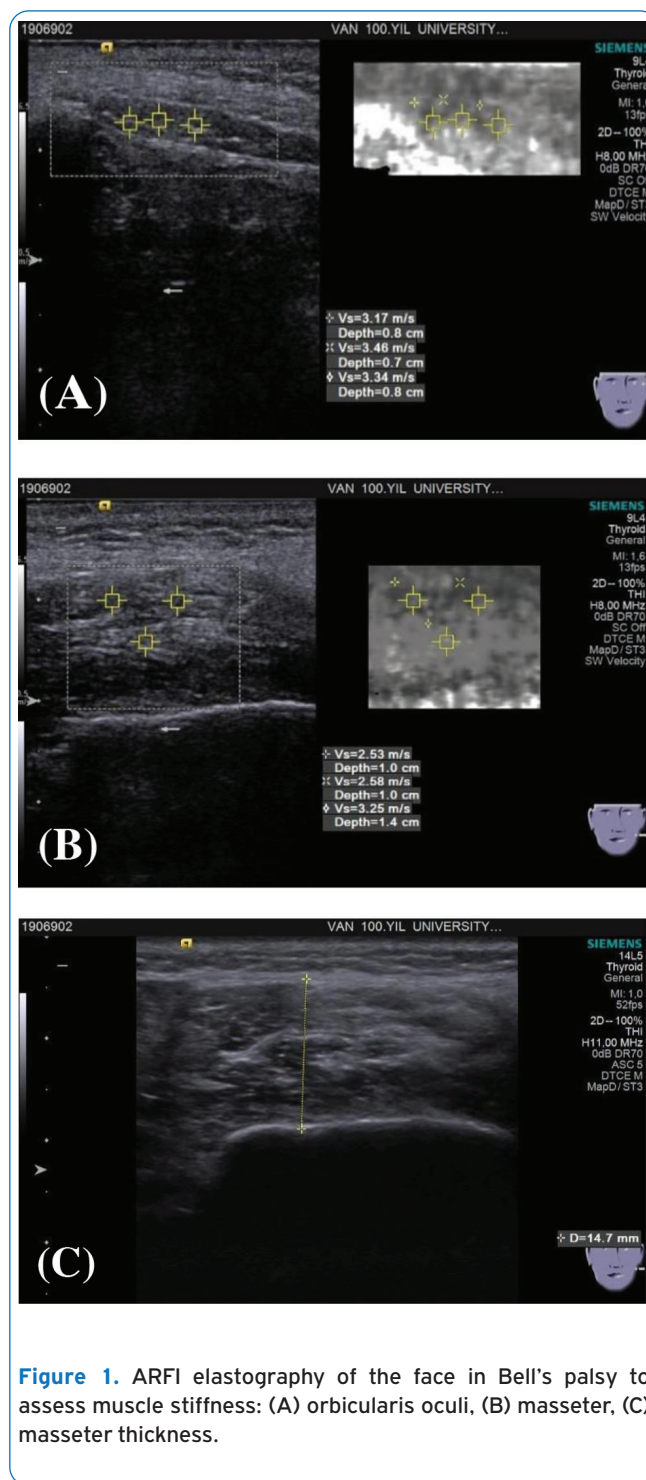


Figure 1. ARFI elastography of the face in Bell's palsy to assess muscle stiffness: (A) orbicularis oculi, (B) masseter, (C) masseter thickness.

variables was tested with the Kolmogorov-Smirnov test. A comparison was made between the data before and after treatment using the paired t -test. We carried out a Pearson correlation analysis to determine the linear relationships among variables. Statistical analysis was performed using SPSS software version 23.0 (SPSS Inc., Chicago, IL, USA). The level of statistical significance (p -value) was set at 5%.

Results

The study comprised 35 patients initially diagnosed with facial palsy. After applying the inclusion and exclusion criteria, five patients were excluded from the study (three due to missing data and two due to loss to follow-up). Consequently, 30 patients were included in the study (17 females, 13 males, mean age of 44.6 ± 16.76 years, range: 18-72). The average symptom duration was 1.97 ± 0.91 months. ARFI analyses were conducted for the masseter and orbicularis oculi, whereas the nasalis was evaluated electrophysiologically (EMG). Table 1 presents various descriptive characteristics such as sociodemographic, clinical, and laboratory data.

Lower EMG-orbicularis oculi and ARFI-masseter values were observed on the paretic side compared to the nonparetic side ($p < .001$). There was no significant difference in EMG-nasalis, ARFI-orbicularis oculi, and ARFI-masseter thickness parameters between the paretic and nonparetic sides (Table 2).

The initial degree of facial nerve paralysis was 5.13 ± 0.89 on the House-Brackmann scale (range 4-6). This parameter significantly decreased after the treatment, measuring 2.53 ± 0.81 . There was a significant difference between the pre- and post-treatment periods regarding EMG-orbicularis oculi, EMG-nasalis, ARFI-masseter, and ARFI-orbicularis oculi parameters ($p < .001$). These parameters were significantly lower during the pretreatment period compared to the post-treatment period ($p < .001$). There was no significant difference in ARFI-masseter thickness between the pre- and post-treatment periods (Table 3).

In addition, no significant correlations were found between EMG and ARFI-elastography parameters (Table 4), as demonstrated by the correlation analysis.

Discussion

This study aimed to assess the usefulness of elastography for diagnosing and monitoring Bell's palsy. After the 4-week treatment period, we compared pre- and post-treatment measurements to evaluate elastography. When we compared the affected with the unaffected side, EMG values and ARFI values were lower on the paretic side, especially for the orbicularis oculi and the masseter. After treatment, EMG (orbicularis oculi, nasalis) and ARFI (masseter, orbicularis oculi) values improved compared with baseline. There was no significant correlation between the EMG and ARFI parameters.

A significant challenge encountered in clinical practice pertains to the paucity of objective measurement tools to assess facial paralysis diagnosis and treatment progress. Clinical measurements, such as the House-Brackmann grading, can provide some information about a patient's condition. Electromyography and other nerve conduction techniques are intrusive procedures with limited clinical utility in the diagnosis and follow-up of specific medical

Table 1. Socio-demographic and clinical characteristics of patients with Bell's palsy.

	Bell's palsy (n=30)
Age, years, (mean \pm SD)	44.6 \pm 16.76
Sex, F/M, n (%)	17/13
Affected side, R/L	19/11
Symptom duration, months	1.97 \pm 0.91
BMI, (kg/m ²), (mean \pm SD)	25.2 \pm 2.1
Smoking, n (%)	12 (40%)
HB-grade, n(%);	
Grade 4	6 (20%)
Grade 5	12 (40%)
Grade 6	12 (40%)
Hypertension, n (%)	4 (13.3%)
Diabetes mellitus, n (%)	6 (20%)
ESR, (mm/h)	10.93 \pm 5.47
CRP, (mg/l)	3.73 \pm 1.77
Serum creatinine, mg/dL	0.83 \pm 0.14
AST, U/L	20.76 \pm 6.47
<i>F/M, female/male; R/L, right/left; BMI, body mass index; HB grade, House-Brackmann grade; ESR, erythrocyte sedimentation rate; CRP, c-reactive protein; AST, aspartate aminotransferase; SD, standard deviation.</i>	

conditions. The effectiveness of various electrophysiological tests in predicting outcomes for acute facial paralysis is still a topic of debate¹⁴.

Ultrasonography is a non-invasive technique that does not expose patients to radiation and is easily accessible. It has the potential to be a useful diagnostic and monitoring tool for facial muscle disorders^{12,13}. Elastography is a novel method that can accurately and non-invasively measure muscle tone. It is an objective technique that provides reliable results. This method can indirectly inform us about muscle tonus and help us evaluate the efficacy of treatments in these patients¹⁵. Muscle atrophy occurs as a secondary effect of denervation. In this condition, loss of nerve supply results in the accumulation of adipose and fibrous tissue in the surrounding area. An increase in fibrous tissue correlates with a higher ultrasound echo intensity¹⁶.

Only a limited number of studies have assessed the elastosonographic features of facial muscles in patients with Bell's palsy^{12,13}. The aforementioned studies have primarily focused on diagnosis and haven't addressed the follow-up process. Our follow-up evaluations demonstrated improvement in both EMG and ARFI values, as indicated by pre- and post-treatment assessments. This result suggests that ARFI-elastosonography may have the potential for use in the follow-up of patients with Bell's palsy to monitor their recovery.

Table 2. Electromyography and ARFI-elastographic characteristics.

		Affected side (n = 30) (mean ± SD)	Unaffected side (n = 30) (mean ± SD)	p value	Cohen d
House-Brackmann grade		5.13 ± 0.89	1.00 ± 0.01	0.001	8.14
EMG	Orbicularis oculi (mV)	0.48 ± 0.49	2.10 ± 0.48	0.001	3.34
	Nasalis (mV)	4.31 ± 0.64	4.61 ± 0.59	0.069	0.48
ARFI-elastography	Masseter (m/s)	3.16 ± 0.55	4.41 ± 0.76	0.001	1.88
	Orbicularis oculi (m/s)	2.43 ± 0.41	2.25 ± 0.55	0.152	0.37
Masseter thickness (mm)		12.44 ± 2.21	13.35 ± 1.93	0.093	0.44

EMG, electromyography; ARFI, acoustic radiation force impulse; Effect size: Cohen's d computed as the standardized mean difference using the pooled SD.

Table 3. Comparison of the pre- and post-treatment values of patients diagnosed with Bell's palsy on the affected side.

		Before treatment (baseline) (mean ± SD)	After treatment (4 th week) (mean ± SD)	p value	Cohen d
House-Brackmann grade		5.13 ± 0.89	2.53 ± 0.81	0.001	2.98
EMG	Orbicularis oculi (mV)	0.48 ± 0.49	1.70 ± 0.54	0.001	2.30
	Nasalis (mV)	4.31 ± 0.64	4.70 ± 0.50	0.001	0.66
ARFI-elastography	Masseter (m/s)	3.16 ± 0.55	3.68 ± 1.02	0.019	0.62
	Orbicularis oculi (m/s)	2.43 ± 0.41	2.91 ± 0.46	0.001	1.73
Masseter thickness (mm)		12.44 ± 2.21	12.56 ± 2.44	0.281	0.07

EMG, electromyography; ARFI, acoustic radiation force impulse; Effect size: Cohen's d computed as the standardized mean difference using the pooled SD.

Table 4. Pearson correlation between EMG and ARFI elastography.

	EMG - Orbicularis oculi	EMG- nasalis	Elasto -masseter	Elasto- orbitalis oculi	Masseter thickness (mm)
EMG-Orbicularis oculi	1				
EMG-Nasalis	0.066	1			
Elasto-Masseter	-0.351	0.030	1		
Elasto-Orbicularis oculi	0.122	0.155	0.434*	1	
Masseter thickness (mm)	0.134	0.111	-0.070	0.051	1

*EMG, electromyography; ARFI, acoustic radiation force impulse; SD, standard deviation. *: p<0.05.*

Although the values for EMG-orbicularis oculi and ARFI-masseter values were significantly lower on the paretic side, we did not observe a significant correlation between our patients' EMG and ARFI parameters. Previous studies have suggested that quantitative ultrasonography can be beneficial for evaluating facial muscle status and confirming the results of facial EMG in patients with facial

palsy. Contrary to their findings, Volk et al.¹³ found a significant correlation between ultrasonography and EMG, particularly in the orbicularis oculi and frontalis muscles. There can be several reasons for this difference. Firstly, several factors influence facial muscle thickness, including age, sex, and morphology. Furthermore, muscles exhibit anisotropy, which means their response varies depending

on the direction of the applied force. Patients with immobility or paralysis may develop muscle weakness because fatty and fibrous connective tissue accumulates in the interstitial spaces¹⁸. There is a correlation between the amount of fibrous tissue and the level of ultrasound echo intensity. As the amount of fibrous tissue increases, so does the ultrasound echo intensity¹⁶. Lastly, the quality of the images depends on the operator, and ultrasound imaging is not a standardized process.

As per Khan et al.²⁰, a recent systematic review confirmed the benefits of physical therapy in the early stages of Bell's palsy recovery. Lee et al. reported that ultrasound in patients with severe Bell's palsy can show the affected muscles and degree of degeneration and can help guide rehabilitation²¹. Elastography is a method for detecting changes in the stiffness of the facial muscles¹⁸. The literature suggests that elastography is a reliable indicator of changes in masseter muscle stiffness following physical therapy, including massage¹⁹, exercise²², FES (functional electrical stimulation)^{23,24}, and TENS (transcutaneous electrical nerve stimulation)²⁵. Our findings are consistent with the presented results on echo intensity in mimic muscles during denervation. In BP, the facial muscles (e.g., orbicularis oris, buccinator, and zygomaticus major) are affected, while the masseter muscle (CN V) is usually unaffected. Owing to its close anatomical relationship, the masseter may contribute to facial expressions by working in conjunction with the facial muscles. Researchers use the masseter as a "control muscle." Moreover, some studies include the masseter muscle in rehabilitation and neuromuscular synchronization.

It is essential to consider certain limitations for this study. First, the study's power may have been adversely affected by the limited sample size of subjects. Second, ARFI elastosonography was performed on a limited number of facial muscles, specifically the masseter and orbicularis oculi; nasalis was evaluated by EMG only. These limitations may have affected the study results, especially in the correlation analysis. Third, the study lacked a healthy control group, which limits the strength of the conclusions. To address this issue, the unaffected side was used as the control group. Another limitation is that intra- and inter-operator variability analysis cannot be completed/ reported, and operator dependency remains a limitation. Last, the overuse of the healthy side's muscles can cause them to enlarge, which in turn can cause the paralyzed side's relative atrophy to be overestimated.

Conclusions

To conclude, ARFI elastosonography can be a valuable diagnostic and monitoring tool for patients with Bell's palsy. Nevertheless, there is a lack of standardization in the field, and larger randomized controlled studies are necessary to determine the possible relationship between muscle stiffness and EMG.

Ethics Approval

The study protocol was approved by the Ethics Committee of the University Hospital (B.30.2.YYUO.01.00.00/63). The study was conducted in accordance with the Declaration of Helsinki (1964) and its later amendments.

Consent to Participate

Written informed consent was obtained from all the study participants.

Authors' Contributions

Conceptualization, M.T, N.T, M.R.O and A.B.; methodology, M.T, A.Y and A.B.; formal analysis, M.T, N.B.; A.B; investigation, M.T, A.Y, M.R.O and A.B; data curation, M.T, N.T, A.B, and N.B.; writing—original draft preparation, M.T, and M.R.O.; writing—review and editing, M.T, N.T, M.R.O, A.Y., and N.B. Supervision: M.T, N.B. All authors have read and approved the final version of the manuscript.

Acknowledgments

We thank Prof. Dr. Siddık Keskin for his statistical comments and analysis.

References

1. Lan D, Deng W, He K, et al. Acupuncture treatment of a pregnant patient with Bell's palsy in the third trimester: case report. *Front Neurol*. 2023;4:13;1088138.
2. Bozan N, Koçak ÖF, Demir CY, et al. Serum levels of heavy metals in patients with Bell's palsy: a case-control study. *Eur Arch Otorhinolaryngol*. 2024;281(2):891-6.
3. Shafshak TS. The treatment of facial palsy from the point of view of physical and rehabilitation medicine. *Eura Medicophys*. 2006;42(1):41-7.
4. Zandian A, Osiro S, Hudson R, et al. The neurologist's dilemma: a comprehensive clinical review of Bell's palsy, with emphasis on current management trends. *Med Sci Monit*. 2014;20:83-90.
5. Pauna HF, Silva VAR, Lavinsky J, et. al. Task force of the Brazilian Society of Otology - evaluation and management of peripheral facial palsy. *Braz J Otorhinolaryngol*. 2024;90(3): 101374.
6. Fonseca KM, Mourão AM, Motta AR, Vicente LC. Scales of degree of facial paralysis: analysis of agreement. *Braz J Otorhinolaryngol*. 2015;81(3):288-93.
7. Petrides GA, Hayler R, Lee JW, Jankelowitz S, Low TH. Electromyography in the prognostication of recovery in patients with acute peripheral facial nerve palsy: A systematic review. *Clin Otolaryngol*. 2023;48(4):563-75.
8. Eviston TJ, Chong LSH, Kwai NCG, Clark JR, Krishnan AV. Altered axonal excitability properties in facial palsy. *Muscle Nerve*. 2018;57(2):268-72.
9. Lima KMME, Costa Júnior JFS, Pereira WCA, Oliveira LF. Assessment of the mechanical properties of the muscle-tendon unit by supersonic shear wave imaging elastography: a review. *Ultrasonography*.

- 2018;37(1):3-15.
10. Snoj Ž, Wu CH, Taljanovic MS, Dumić-Čule I, Drakonaki EE, et. al. Ultrasound Elastography in Musculoskeletal Radiology: Past, Present, and Future. *Semin Musculoskelet Radiol.* 2020;24(2):156-66.
 11. Nightingale K. Acoustic Radiation Force Impulse (ARFI) Imaging: a Review. *Curr Med Imaging Rev.* 2011;7(4):328-39.
 12. Volk GF, Pohlmann M, Sauer M, Finkensieper M, Guntinas-Lichius O. Quantitative ultrasonography of facial muscles in patients with chronic facial palsy. *Muscle Nerve.* 2014;50(3):358-65.
 13. Volk GF, Leier C, Guntinas-Lichius O. Correlation between electromyography and quantitative ultrasonography of facial muscles in patients with facial palsy. *Muscle Nerve.* 2016;53(5):755-61.
 14. Grosheva M, Wittekindt C, Guntinas-Lichius O. Prognostic value of electroneurography and electromyography in facial palsy. *Laryngoscope.* 2008;118(3):394-7.
 15. Toprak N, Toktas O, Ince S, et al. Does ARFI elastography complement B-mode ultrasonography in the radiological diagnosis of idiopathic granulomatous mastitis and invasive ductal carcinoma? *Acta Radiol.* 2022;63(1):28-34.
 16. Pillen S, Tak RO, Zwarts MJ, et. al. Skeletal muscle ultrasound: correlation between fibrous tissue and echo intensity. *Ultrasound Med Biol.* 2009;35(3):443-6.
 17. Olchowy A, Seweryn P, Olchowy C, Wieckiewicz M. Assessment of the masseter stiffness in patients during conservative therapy for masticatory muscle disorders with shear wave elastography. *BMC Musculoskelet Disord.* 2022;11;23(1):439.
 18. Olchowy C, Więckiewicz M, Sconfienza LM, et. al. Potential of Using Shear Wave Elastography in the Clinical Evaluation and Monitoring of Changes in Masseter Muscle Stiffness. *Pain Res Manag.* 2020;12;2020:4184268.
 19. Sauer M, Guntinas-Lichius O, Volk GF. Ultrasound echomyography of facial muscles in diagnosis and follow-up of facial palsy in children. *Eur J Paediatr Neurol.* 2016;20(4):666-70.
 20. Khan AJ, Szczepura A, Palmer S, et al. Physical therapy for facial nerve paralysis (Bell's palsy): An updated and extended systematic review of the evidence for facial exercise therapy. *Clin Rehabil.* 2022;36(11):1424-49.
 21. Lee JH, Park IS, Kim J. Ultrasonographic findings of facial muscles in patients with severe facial palsy who showed no improvement for more than 3 months on acute stage. *Eur Arch Otorhinolaryngol.* 2024;281(4):2001-10.
 22. Olchowy C, Grzech-Leśniak K, Hadzik J, Olchowy A, Łasecki M. Monitoring of Changes in Masticatory Muscle Stiffness after Gum Chewing Using Shear Wave Elastography. *J Clin Med.* 2021;3;10(11):2480.
 23. Tuncay F, Borman P, Taşer B, Ünlü İ, Samim E. Role of electrical stimulation added to conventional therapy in patients with idiopathic facial (Bell) palsy. *Am J Phys Med Rehabil.* 2015;94(3):222-8.
 24. Meincke G, Krauß J, Geitner M, Kuttnerreich AM, Arnold D, Ballmaier J, Lehmann T, Mayr W, Guntinas-Lichius O, Volk GF. Deceleration of denervated facial muscle atrophy through functional electrical stimulation: a sonographic quantification in patients with facial nerve paralysis. *Eur J Transl Myol.* 2024;13;34(4):13162.
 25. Mäkelä E, Venesvirta H, Ilves M, Lylykangas J, Rantanen V, Ylä-Kotola T, Suominen S, Vehkaoja A, Verho J, Lekkala J, Surakka V, Rautiainen M. Facial muscle reanimation by transcutaneous electrical stimulation for peripheral facial nerve palsy. *J Med Eng Technol.* 2019;43(3):155-64.