

Case Report

Tendinopathy Pain Mimicking Neuropathy on Nerve Conduction Study Resolved with Ultrasound-Guided Steroid Injection Treatment: A Case Report

Fred Yi-Shueh Chen¹, Dean Yin-Kai Huang¹¹Department of Physical Medicine and Rehabilitation, Taipei Medical University Hospital, Taipei, Taiwan (R.O.C.)**Abstract**

We describe the case of a 41-year-old Asian man who was initially given a diagnosis of peroneal neuropathy but who later received a diagnosis of tenosynovitis of extensor digitorum longus (EDL). The patient initially presented with left lateral ankle numbness, pain, and decreased range of dorsiflexion after an 8-km walk. Peroneal neuropathy was first diagnosed on the basis of reduced compound muscle action potential (CMAP). Conversely, ankle ultrasound revealed normal peroneal nerve but considerable EDL tenosynovitis. Ultrasound-guided injection of triamcinolone and lidocaine into the tendon sheath was performed for pain relief. At 1-month follow-up, CMAP amplitude was restored, and ultrasound imaging revealed normal EDL structure without signs of tenosynovitis. This case serves as a reminder that clinicians must pay attention to multiple factors affecting CMAP, including tendinopathy and pain, to avoid misinterpretation.

Keywords: Case Report, Compound Muscle Action Potential, Nerve Conduction Study, Neuropathy, Tendinopathy**Introduction**

Compound muscle action potential (CMAP) amplitude is measured in nerve conduction studies (NCS). CMAP amplitude represents the functioning axons within a nerve and depolarization of underlying muscle fibers¹. A lower than average CMAP amplitude can suggest either a loss of motor axons, failed action potential propagation, futile neuromuscular junction transmission, or primary muscle disease². In a standard CMAP study, the nerve must be supramaximally stimulated to prevent technically induced low CMAP. Certain physiological factors, such as skin impedance, subcutaneous edema, fibrosis, or obesity, can result in understimulation and low CMAP, potentially resulting

in a false positive indication of disease³. Therefore, CMAP findings should be cautiously interpreted, and submaximal stimulation should be avoided. Few case reports involving patients with tendinopathy and pain have reported low CMAP amplitudes. The present case report describes our experience in managing a patient with tingling pain and limited ankle dorsiflexion due to tendinopathy mimicking the presentation of neuropathy. The patient received an ultrasound-guided corticosteroid injection for pain relief, and after 1 month, CMAP amplitude and muscle strength had been restored.

Case presentation

A 41-year-old Asian man visited our university hospital clinic due to left lateral ankle pain that had been ongoing for 2 days. The patient reported no past health problems and was in good overall condition. The pain had started after the patient completed a brisk walk of approximately 8 km. According to the patient's smartwatch, the walk involved 10,000 steps over flat terrain. The patient described the pain as similar to that of an ankle sprain. The pain was aggravated by ankle inversion and relieved when the ankle was placed in the dorsiflexion position. At work on the day after the walk, the patient had only been able to walk on his left heel. The patient visited our university hospital clinic for

The authors have no conflict of interest.

Corresponding author: Dean Yin-Kai Huang, Department of Physical Medicine and Rehabilitation, Taipei Medical University Hospital, Taipei 11031, Taiwan (R.O.C.) No. 252, Wuxing St., Xinyi Dist., Taipei, 11031, Taiwan

E-mail: dean.huang.tw@gmail.com

Edited by: G. Lyritis

Accepted 22 October 2024



Table 1. Nerve conduction study of a patient with tendinopathy in left extensor digitorum longus mimicking left peroneal motor neuropathy.

Stimulation Site	Initial presentation				One month after treatment			
	Latency (ms)	Amplitude (mV)	Duration (ms)	Velocity (m/s)	Latency (ms)	Amplitude (mV)	Duration (ms)	Velocity (m/s)
Left Deep Peroneal Motor (Extensor Digitorum Brevis)								
Anterior Ankle	3.7	2.2	13.20	-	4.0	5.0*	11.41	-
Fibula Head	11.3	1.8	12.58	45.5	13.0	4.9*	9.69	44.9
Right Deep Peroneal Motor (Extensor Digitorum Brevis)								
Anterior Ankle	3.7	4.2	8.52	-	4.1	4.6	10.94	-
Fibula Head	12.5	4.0	8.75	48.8	12.4	4.5	9.77	45.8
Left Superficial Peroneal Antidromic Sensor (Anterior lateral malleolus)								
Anterior Calf	1.7	7.5	0.94	38.6	1.8	9.2	1.53	40.8
Right Superficial Peroneal Antidromic Sensor (Anterior lateral malleolus)								
Anterior Calf	2.4	8.7	1.44	42.4	2.4	9.0	1.47	41.7
Left Tibial Motor (Abductor Hallucis Brevis)								
Medial Ankle	3.6	13.4	11.56	-	-	-	-	-
Popliteal Fossa	12.0	10.5	14.30	48.8	-	-	-	-

* CMAP amplitude in the left peroneal nerve was restored 1 month after an intra-tendon corticosteroid injection.

further evaluation. Upon examination, the patient presented weakness in performing left ankle dorsiflexion with grade 4 on manual muscle testing compared to full muscle strength on the right ankle. Pain intensity of 7 on visual analogue scale (VAS) was noted while trying to attempt left ankle eversion and toe extension. In addition, talar tilt test was positive and foot palpation showed tenderness with tingling over left lateral ankle and dorsal foot with extension to toes. Swelling, local heat, erythema, and muscular atrophy were not observed. An NCS of the lower limbs and an ultrasound study of the left ankle were ordered.

Nerve conduction was studied through readings taken from the extensor digitorum brevis while stimulating the peroneal nerve at the ankle and the fibular head. Electromyography was performed using a Medelec Synergy system (Medelec Biomedical, Surrey, UK). Initially, a low CMAP amplitude was observed in the left deep peroneal nerve (2.2 mV from anterior ankle and 1.8 mV from fibula head) with normal distal latency and velocity (Table 1). CMAP amplitude was 52% lower in the left peroneal nerve than in the right peroneal nerve. Left superficial peroneal sensory and tibial motor nerve studies revealed normal latency, velocity, and amplitude. Initial NCS results indicated left peroneal axonal neuropathy.

Ultrasound was ordered to assess for contributing anatomic abnormalities, specifically the left peroneal nerve. Sonographic examination did not reveal ligamentous or deep peroneal nerve abnormalities; however, mild enlargement and increased hypoechogenicity of the extensor digitorum

longus (EDL) tendon without tear and focal circumferential hypoechoic distention of the EDL tendon sheath were observed (asterisks in Figure 1A and 1D). EDL tenosynovitis was suspected and ultrasound-guided injection into the EDL tendon sheath of triamcinolone (20 mg / 0.5 mL) mixed with 1% lidocaine (0.5 mL) was performed (Figure 1B). Pain relief was immediate following the injection, with the patient reporting a pain intensity of 2 on the VAS, down from 7. The patient had resumed full normal activity and a normal ambulatory state 4 days later.

A 1-month follow-up NCS revealed that the left peroneal CMAP amplitude had returned to normal (5.0 mV; Table 1). No pain or tenderness were observed on palpation, and the patient reported a pain intensity 0 of the VAS. Follow-up ultrasound on the ankle revealed normal EDL with no tendon thickening or tendon sheath fluid (Figure 1C and 1D). We concluded that the patient had experienced EDL tendinopathy that mimicked neuropathy on NCS. The tendinopathy had been successfully treated using an ultrasound-guided steroid injection for pain relief, and restoration of normal CMAP had been achieved by the 1-month follow-up.

Discussion

Symptoms presenting as numbness, tingling, pain, or weakness benefit from NCS for identifying whether peripheral neuropathy is present⁴. Quantitative assessment of peripheral nerve and muscle function helps clinicians determine the physiological sources of patients' symptoms⁵.

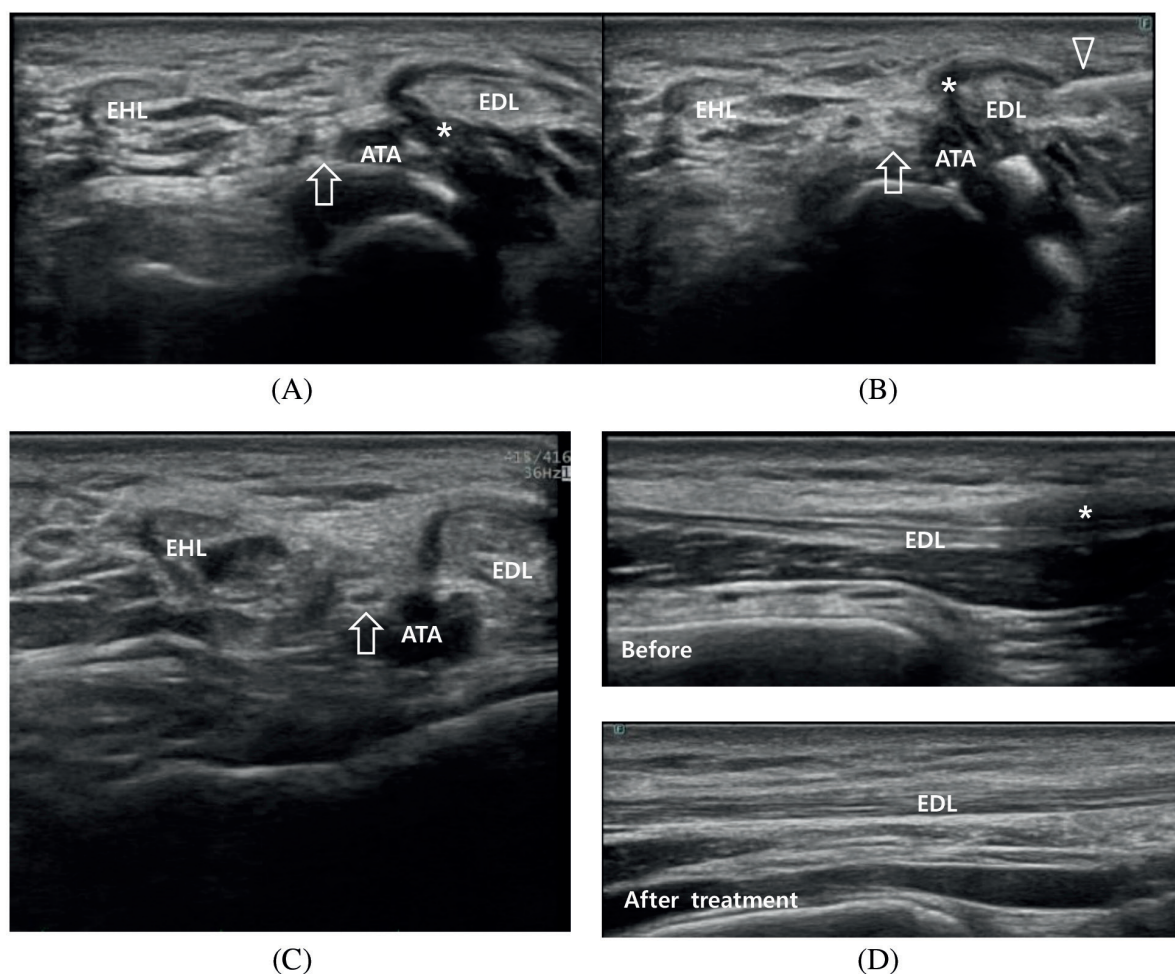


Figure 1. Ultrasound of left ankle. (A) Extensor digitorum longus (EDL) tendon with focal tenosynovitis (asterisk) on initial examination in short-axis view. Note normal deep peroneal nerve (arrow) and anterior tibial artery. (B) Ultrasound-guided injection within tendon sheath by needle tip (arrowhead) in short-axis view. Note that the deep peroneal nerve (arrow) is not infiltrated by lidocaine. (C) Short-axis view 1 month later with decreased hypoechoogenicity and tendon sheath fluid surrounding the EDL. (D) Long-axis view before and 1 month after treatment shows resolution of EDL tenosynovitis.

Our case is an incidental finding featuring low CMAP during acute onset of pain from tendinopathy, mimicking that of neuromuscular disease on NCS.

The cause of reduced CMAP amplitude in this case was likely multifactorial. Tenosynovial fluid might have reduced conduction efficiency to a degree that would be observed when conducting an NCS on edematous limbs. Alternatively, tendon swelling may have caused focal nerve compression; however, focal nerve compression was not observed during initial ultrasound imaging. We conjecture that muscle length, affected by pain from tendinopathy, was the cause of the reduced CMAP amplitude.

Several studies with readings taken from the abductor pollicis brevis in healthy individuals have demonstrated that

muscle length may alter CMAP waveform parameters⁶⁻⁷. Hashimoto et al. found that muscle lengthening decreased CMAP amplitude with a concomitant increase in duration, whereas muscle shortening increased CMAP amplitude with a concomitant reduction in duration⁶. In our case, lateral ankle pain prevented the patient from performing ankle eversion and toe extension. Therefore, whether the patient was in a neutral position during the NCS and the potential effects of muscle length and contraction were unknown. We emphasize the importance of monitoring the position of the recorded muscle upon stimulation and remind operators and clinicians to differentiate between waveform changes caused by muscle length changes and those resulting from nerve lesions.

Muscle weakness frequently accompanies conditions with musculoskeletal pain. According to the pain adaptation model developed by Lund et al., pain reduces muscle excitability and the ability to contract one's muscles⁸⁻¹⁰. This suggests that the observed decrease in CMAP amplitude may be due to reduced muscle fiber excitability. However, other studies have not observed reduced CMAP amplitudes after pain was evoked using hypertonic saline injection. Several studies have reported no difference in CMAP latency and amplitude before versus after injection of hypertonic saline into muscle¹¹⁻¹². However, a recent study by Duez et al. revealed reduced amplitudes of potentials obtained by direct muscle stimulation and by nerve stimulation in subjects with hypertonic saline injection-evoked pain in the biceps brachii¹³. Few studies have investigated the effects of experimental pain on muscle fiber excitability, as measured by the amplitudes of evoked potentials. Assuming that the pain adaptation model functions as useful reflex to reduce further injury and pain, evoked pain likely leads to a decrease in muscle fiber excitability and thereby has a peripheral effect on the muscle and affects quantitative values on NCS.

Tendinopathy can cause pain and weakness, and tenosynovitis is suspected when symptoms of swelling, pain, or tenderness along the course of the tendon occur¹⁴. A systematic review concluded that steroid injections provide short-term pain relief¹⁵. The decreased VAS score in the present report suggests that treatment with corticosteroid injection was effective, and the normal CMAP amplitude observed at the 1-month follow-up may be due to decreased tenosynovitis, reduced pain, normal muscle excitability, or surviving motor units reinnervating. Further research is warranted to correlate pain and tendinopathy affecting NCS quantitative measurement, aside from commonly known intrinsic physiological or extrinsic technical factors.

Conclusion

This report describes a rare case of an incidental finding where acute tendinopathy showed low CMAP amplitude on NCS, mimicking peripheral neuropathy. We demonstrated pain relief after ultrasound-guided steroid injection and restoration of CMAP amplitude on follow-up examination. This case serves as a valuable reminder to clinicians and NCS operators to pay attention to the patient's condition because unknown intrinsic and extrinsic variables may affect quantitative measurements and result in misinterpretation. The degree of tendinopathy severity that might affect CMAP amplitude is unknown. Further study is necessary to elucidate the peripheral effect of pain on muscle excitability, contraction, and length and the interplay of these factors with CMAP waveforms.

References

1. Caress JB, Gregory JE, Seward BR. Neurophysiology of Nerve Conduction Studies. In: Andrew SB, Seward BR, editors. *The Clinical Neurophysiology Primer*: Humana

- Press; 2007, p.207-16.
2. Chung T, Prasad K, Lloyd TE. Peripheral neuropathy: clinical and electrophysiological considerations. *Neuroimaging Clin N Am* 2014;24(1):49-65.
3. Rubin DI. Technical Issues and Potential Complications of Nerve Conduction Studies. In: Rubin DI, editor. *Clinical Neurophysiology*: Oxford University Press; 2021. p. 431-98.
4. Castelli G, Desai KM, Cantone RE. Peripheral Neuropathy: Evaluation and Differential Diagnosis. *Am Fam Physician* 2020;102(12):732-739.
5. Kimura J. Electrical Properties of Nerve and Muscle. *Electrodiagnosis in Diseases of Nerve and Muscle: Principles and Practice*: Oxford University Press; 2013. p. 22-33.
6. Hashimoto S, Kawamura J, Segawa Y, Harada Y, Hanakawa T, Osaki Y. Waveform changes of compound muscle action potential (CMAP) with muscle length. *J Neurol Sci* 1994;124(1):21-24.
7. Kim BJ, Date ES, Park BK, Choi BY, Lee SH. Physiologic changes of compound muscle action potentials related to voluntary contraction and muscle length in carpal tunnel syndrome. *J Electromyogr Kinesiol* 2005;15(3):275-281.
8. Lund JP, Donga R, Widmer CG, Stohler CS. The pain-adaptation model: a discussion of the relationship between chronic musculoskeletal pain and motor activity. *Can J Physiol Pharmacol* 1991;69(5):683-694.
9. Sterling M, Jull G, Wright A. The effect of musculoskeletal pain on motor activity and control. *J Pain* 2001;2(3):135-145.
10. Le Pera D, Graven-Nielsen T, Valeriani M, et al. Inhibition of motor system excitability at cortical and spinal level by tonic muscle pain. *Clin Neurophysiol* 2001;112(9):1633-1641.
11. Farina D, Arendt-Nielsen L, Graven-Nielsen T. Experimental muscle pain decreases voluntary EMG activity but does not affect the muscle potential evoked by transcutaneous electrical stimulation. *Clin Neurophysiol* 2005;116(7):1558-1565.
12. Qerama E, Fuglsang-Frederiksen A, Kasch H, Bach FW, Jensen TS. Effects of evoked pain on the electromyogram and compound muscle action potential of the brachial biceps muscle. *Muscle Nerve* 2005;31(1):25-33.
13. Duez L, Qerama E, Jensen TS, Fuglsang-Frederiksen A. Modulation of the muscle and nerve compound muscle action potential by evoked pain. *Scand J Pain* 2015;6(1):55-60.
14. Peters SE, Laxer RM, Connolly BL, Parra DA. Ultrasound-guided steroid tendon sheath injections in juvenile idiopathic arthritis: a 10-year single-center retrospective study. *Pediatr Rheumatol Online J* 2017;15(1):22.
15. Coombes BK, Bisset L, Vicenzino B. Efficacy and safety of corticosteroid injections and other injections for management of tendinopathy: a systematic review of randomised controlled trials. *Lancet* 2010;376(9754):1751-1767.